

Diagnosis and Management of Flat and Polypoid Dysplasia in Inflammatory Bowel Disease

Francis A. Farraye, MD, MSc

Clinical Director, Section of Gastroenterology, Boston Medical Center
Professor of Medicine, Boston University School of Medicine, Boston, MA

Bullet Points

- Patients with long-standing ulcerative colitis are at an increased risk for developing dysplasia and colorectal carcinoma.
- Colonoscopy is currently the best and most widely used method to detect dysplasia and cancer in IBD patients.
- The finding of flat HGD or carcinoma in endoscopic biopsy samples is an indication for colectomy; colectomy may also be indicated for flat LGD.
- Patients with one or more biopsies reported “indefinite for dysplasia,” follow-up surveillance examination should be performed within 3-6 months.
- Patients with adenoma-like DALMs may be treated adequately by polypectomy and continued surveillance in contrast to non adenoma-like DALMs, which still remain an indication for colectomy.
- Newer techniques are being used or are under investigation to facilitate the identification of dysplastic lesions in patients with IBD.

Patients with long-standing ulcerative colitis are at an increased risk for developing dysplasia and colorectal carcinoma (CRC). This risk approaches 8% by 20 years and 18 % by 30 years (1, 2). Recent data suggests that the risk of CRC in patients with ulcerative colitis may be lower than previously reported (3-5). Several possible explanations proposed for this apparent decrease in risk of developing dysplasia and CRC includes a combination of the widespread use of maintenance medical therapy and surveillance colonoscopy as well as more judicious reliance on colectomy. Patients with extensive Crohn’s colitis also have an increased risk of CRC and should undergo regular surveillance (6). Regular communication between the physician performing gastrointestinal endoscopy and the pathologist can improve the care of patients with gastrointestinal disorders in general and inflammatory bowel disease (IBD) in particular (7).

The American College of Gastroenterology has made interactions between the gastrointestinal endoscopist and pathologist an area for quality improvement in colonoscopy (8).

A number of factors are associated with an increased risk of developing CRC in IBD (9). These include a longer duration of colitis, greater extent of colonic involvement (no increase in proctitis patients, SIR 2.8 [CI: 1.6-4.4] in left sided UC and 14.8 [CI: 11.4-18.9] in pancolitis), family history of colorectal cancer (two fold increase), primary sclerosing cholangitis, young age of IBD onset (some studies) and possibly backwash ileitis. A recent advance has been the appreciation that an increased severity of inflammation identified endoscopically and histologically is associated with cancer risk (10, 11). In one study of 136 control and 68 patients with UC associated CRC by Rutter, multivariate analysis demonstrated that higher degrees of histological inflammation were associated with an increased risk of developing CRC (odds ratio, 4.7; $P < 0.001$) (11). In a second study from Mount Sinai of 418 patients who met inclusion criteria, 15 progressed to advanced neoplasia (HGD or colorectal cancer), and 65 progressed to any neoplasia (LGD, HGD, or colorectal cancer). Univariate analysis demonstrated significant relationships between histologic inflammation over time and progression to advanced neoplasia: hazard ratio, 3.0; 95% CI: 1.4-6.3 (10).

Endoscopic findings may also help in the stratification of patients at highest risk of developing dysplasia or cancer. In one study, the presence of strictures (OR 4.62; CI 1.03-20.8) and pseudopolyps (OR 2.29; CI 1.28-4.11) were both predictors for the development of CRC on multivariate analysis (12). Using these clinical and pathologic factors patients at an increased risk of developing dysplasia and/or CRC can be identified. A number of factors may lower the risk of developing dysplasia and/or CRC. These include prophylactic total proctocolectomy, surveillance programs to detect dysplasia or early stage asymptomatic CRC that include regular

doctor visits, surveillance colonoscopy, and possibly chemoprevention with 5-ASAs, folate, ursodiol, and NSAIDs.

An evidence-based review of published literature (1966-2005), using strict criteria from the Cochrane library, concluded that there was no clear evidence that surveillance colonoscopy prolongs survival in patients with extensive colitis (13). There was evidence that cancers tend to be detected at an earlier stage in patients who are undergoing surveillance, and these patients have a correspondingly better prognosis, but lead-time bias could contribute substantially to this apparent benefit. Finally the authors stated that there is indirect evidence that surveillance is likely to be effective at reducing the risk of death from IBD-associated colorectal cancer and indirect evidence that it may be acceptably cost-effective (13).

At present, despite a lack of evidence from randomized controlled trials surveillance colonoscopy is the best and most widely used method to detect dysplasia and cancer in IBD patients (9, 14-16). However there are several limitations to surveillance colonoscopy and colonoscopy practices are not uniform (17-19). Multiple biopsies are needed and prolong the endoscopic procedure. It has been estimated that 33 biopsies are required to achieve 90% confidence to detect dysplasia if it is present (20). It should be noted that well under 1% of the colonic mucosa is sampled even when multiple random jumbo biopsies are performed. Colonoscopic biopsies should be characterized pathologically as negative, indefinite for dysplasia or positive for low-grade dysplasia (LGD), or high-grade dysplasia (HGD) or carcinoma (21). There are only moderate levels of agreement among pathologists on the diagnosis of dysplasia with better agreement for patients with HGD and negative biopsies rather than LGD or indefinite (21-25). An expert GI pathologist should confirm all cases of dysplasia. Finally, the success of any surveillance program depends on patient compliance with regular colonoscopy.

The finding of flat HGD confirmed by two expert gastrointestinal pathologists, or carcinoma, in endoscopic biopsy samples is an indication for colectomy. In a review of ten prospective surveillance trials of 1225 patients, Bernstein reported that 42% (10 of 24) of patients with HGD who underwent immediate colectomy had synchronous CRC and 32% (15 of 47) of patients with HGD who underwent colectomy at a later date had CRC (26). A study from Rutter and the St. Marks group confirmed these findings (27). In the Rutter study, 45.5% (5 of 11) of patients with HGD undergoing immediate colectomy had cancer in the specimen and for those continuing on surveillance, 25% (2 of 8) developed CRC. In total, 36.8% (7 of 19) of patients with HGD developed CRC.

Although controversial, there is accumulating evidence to suggest that flat LGD is also an indication for colectomy because of the high rate of progression to HGD or cancer in most studies (28-32). In Bernstein's 1994 review, 19% (3 of 19) patients with LGD who underwent immediate colectomy had synchronous CRC and 8% (17/204) of patients with LGD who underwent colectomy at a later date had CRC. Ullman and colleagues from Mount Sinai reported that unexpected advanced neoplasia occurred in 4 of 17 (23.5%) patients who underwent immediate colectomy for flat LGD (2 carcinomas and 2 HGD). On an actuarial basis, the rate of neoplastic progression was 53% at 5 years. In the St. Marks study, 19.6% (9 of 46) of patients with LGD developed CRC, and 39.1% (18 of 46) of patients with LGD developed either HGD or CRC (27). A meta analysis of studies published between 1966 and July 2005 determined the incidence of CRC and the relative risk of developing cancer in UC patients with LGD undergoing surveillance. Twenty surveillance studies with 508 flat LGD or LGD with dysplasia associated lesion or mass were reviewed (33). An average of 18 biopsies taken per colonoscopy (range: 9-24) detected 73 advanced lesions (cancer or high-grade dysplasia) pre-operatively.

When LGD is detected on surveillance there was a 9 fold risk of developing CRC (OR: 9.0, 95% CI: 4.0–20.5) and 12-fold risk of developing any advanced lesion (OR: 11.9, 95% CI: 5.2–27).

Ullman and colleagues noted a 9.0% 5-year progression rate to HGD or CRC in a study of 56 patients with biopsies indefinite for dysplasia. This rate of progression was intermediate between patients with no dysplasia and those with flat LGD (34). The CCFA consensus document recommends that in patients with one or more biopsies reported “indefinite for dysplasia” confirmed by an experienced gastrointestinal pathologist, a follow-up surveillance examination should be performed within 3-6 months (14).

Dysplasia in IBD may occur in flat mucosa (endoscopically invisible and identified by random biopsies) or as an elevated lesion on endoscopy (35-37). In fact in one recent study, most dysplasia (89.3%) found in patients with IBD was elevated (36). With the advent of improved endoscopes and newer adjuvant imaging techniques (chromoendoscopy), the term flat dysplasia may need to be redefined. Blackstone and colleagues first described the term DALM (dysplasia associated lesion or mass) in 1981. In Blackstone’s study of 12 patients with DALMs, 7 were malignant (38). However some raised dysplastic lesions in IBD have endoscopic features similar to adenomas and several reports have described the conservative management of small polypoid dysplastic lesions in patients with IBD (39-41). Raised dysplastic lesions with the appearance of sporadic adenomas have been termed adenoma like DALMs (42). Recent studies have demonstrated that patients with adenoma-like DALMs may be treated adequately by polypectomy and continued surveillance because of their low association with cancer in contrast to non adenoma-like DALMs, which still remain an indication for colectomy because of their high association with cancer (43-47). Odze and colleagues demonstrated that polypoid dysplastic lesions with the appearance of adenomas could be identified and removed by standard endoscopic techniques. In the absence of flat dysplasia surrounding the lesion or elsewhere in the

colon the risk of developing dysplasia or colorectal cancer was low over an 82-month follow-up period (43, 44). Rubin and colleagues reported similar results in a cohort of patients followed for a mean of 49 months (45). Close follow-up endoscopic surveillance is required for patients in which a polypoid dysplastic lesion is removed (46, 48). The presence of HGD in a completely resected polyp does not warrant a change in the recommendation for continued close follow-up (44, 49). It is important that efforts be undertaken to disseminate to gastroenterologists diagnostic and management guidelines of polypoid lesions in IBD (50). Figures 1 A-C and Table 1 contain a series of recommendations based on expert opinion for the performance of surveillance colonoscopy and management of the endoscopic/histologic findings (9).

Newer techniques are needed to facilitate the identification of dysplastic lesions in patients with IBD. Chromoendoscopy is the technique most readily applicable in clinical practice (51-56). Chromoendoscopy can improve the detection of subtle colonic lesions, raising the sensitivity of the endoscopic examination, and improve lesion characterization, increasing the specificity of the examination. Additionally, crypt architecture can be categorized using the pit pattern, aiding differentiation between neoplastic and non-neoplastic changes, and enabling the performance of targeted biopsies. Several different stains have been used including contrast stains (indigo carmine) and vital stains (methylene blue). In the study by Kiesslich, 165 patients with long standing UC were randomized to conventional colonoscopy or colonoscopy with chromoendoscopy using 0.1% methylene blue. More targeted biopsies were possible, and significantly more intraepithelial neoplasia was detected in the chromoendoscopy group (32 vs. 10; $P = 0.003$). The sensitivity and specificity for differentiation between non-neoplastic and neoplastic lesions were 93% (57). In a second back-to-back colonoscopy study, 100 patients with long standing UC underwent conventional colonoscopy with random and directed biopsies followed by spraying with 0.1 % indigo carmine and directed biopsies (58). Extubation times

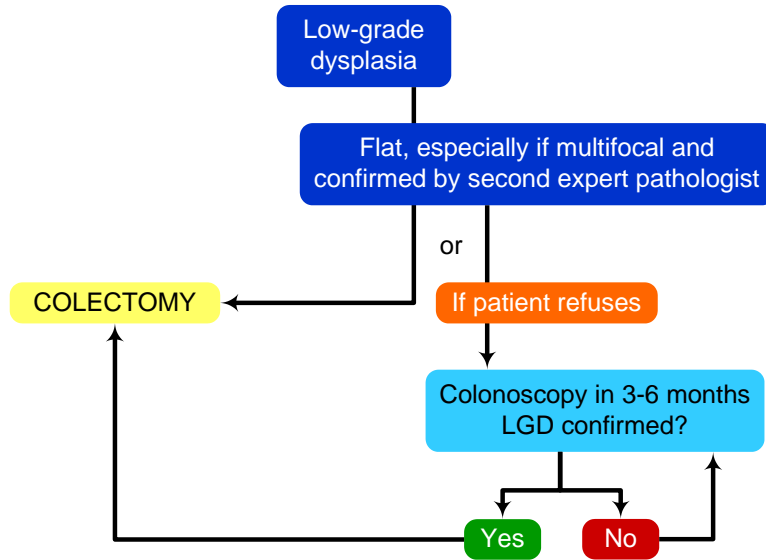
were similar at 10 and 11 minutes. There was no dysplasia in 2904 nontargeted biopsies with 43 mucosal abnormalities in 20 patients in the pre dye spray patients of which two were dysplastic. After spraying an additional 114 abnormalities were seen in 55 patients of which seven were dysplastic. The authors concluded that careful mucosal examination aided by pancolonoscopic chromoendoscopy and targeted biopsies of suspicious lesions may be a more effective surveillance methodology than taking multiple non-targeted biopsies. Longitudinal studies of chromoendoscopy will be needed to determine if the need for colectomy and incidence of CRC is reduced in patients undergoing surveillance with this technology. An atlas of chromoendoscopic images in IBD has been published recently (59).

Investigators are examining the utility of new endoscopic imaging modalities to detect dysplasia in IBD (60). These include narrow band imaging (61, 62), optical coherence tomography, fluorescence endoscopy and confocal laser endomicroscopy (54, 63-66). During confocal endomicroscopy, surface and sub-surface imaging allows the endoscopist to perform a detailed analysis of colorectal crypt architecture and vascular structure. In a randomized trial in 161 UC patients of chromoendoscopy in conjunction with confocal endomicroscopy compared to conventional colonoscopy, the presence of neoplasia could be predicted with 94.7% sensitivity, 98.3% specificity and 97.8% accuracy. By using chromoscopy with endomicroscopy, 4.75-fold more neoplasias could be detected ($P = .005$) than with conventional colonoscopy, although 50% fewer biopsy specimens ($P = .008$) were required. The authors concluded that endomicroscopy based on in vivo histology can determine if UC lesions identified by chromoscopy should undergo biopsy examination, thereby increasing the diagnostic yield and reducing the need for biopsy examinations. Other non endoscopic techniques that may aid in the identification of dysplasia include molecular analysis of colonic biopsies for genomic instability (67-69) and stool based DNA assays (70, 71).

Given the inherent difficulties in the performance of surveillance colonoscopy it has been suggested that chemoprevention be explored as a method to lower the risk of developing dysplasia and CRC in IBD. Chemoprevention refers to the use of drugs to reverse, suppress or to delay the process of carcinogenesis. Several agents have been suggested as chemopreventive agents including folic acid (72, 73), ursodeoxycholic acid (74, 75), NSAIDs (76) and 5ASAs (77-79). A discussion of chemoprevention is beyond the scope of this presentation but the reader is referred to several recent reviews for additional information (80, 81). There is insufficient evidence to modify present screening and surveillance practices in IBD patients on these medications and that chemoprevention is not a substitute for surveillance colonoscopy.

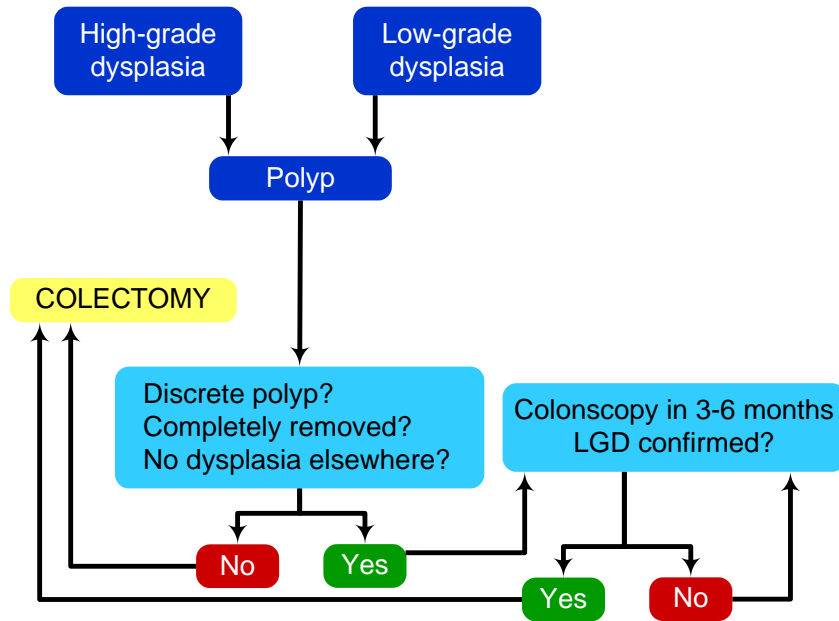
(Please refer to the following article for additional information pertinent to this topic:
Ullman T, Odze R, Farraye FA. Diagnosis and management of dysplasia in patients with ulcerative colitis and Crohn's disease of the colon. *Inflamm Bowel Dis*. 2008.)

Figure 1A. Management of Low Grade Dysplasia in IBD



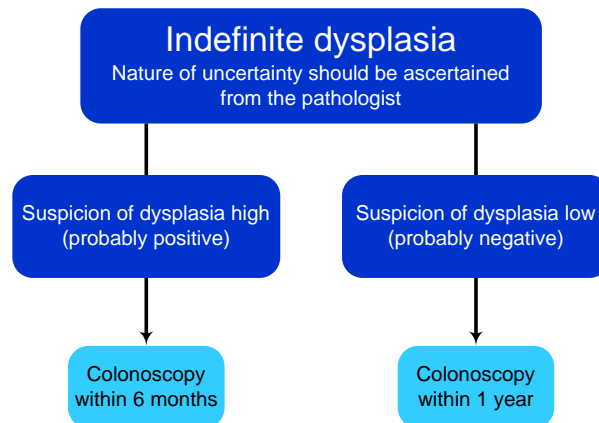
Itzkowitz S., et al, Gastroenterology 2004; 126:1634

Figure 1B. Management of Polypoid Dysplasia in IBD



Itzkowitz S., et al, Gastroenterology 2004; 126:1634

Figure 1C. Management of Indefinite Dysplasia in IBD



Itzkowitz S., et al, Gastroenterology 2004; 126:1634

Table 1: Suggested Performance of Surveillance Colonoscopy

Beginning approximately 7–8 years from the onset of colitis, all patients with UC should undergo an initial screening colonoscopy to determine the extent of colitis and check for neoplasia.
Patients with left-sided colitis should follow the same schedule as those with extensive colitis, although some authorities suggest that regular surveillance for left-sided colitis should begin after 15 years of disease when the risk rises to that of extensive colitis.
In the case of patients with primary sclerosing cholangitis, screening colonoscopy should be carried out at the time the biliary tract disease is diagnosed.
If no dysplasia is detected, patients with extensive colitis (proximal to the hepatic flexure) should have repeat examinations every 1–2 years.
If indefinite dysplasia is reported, the nature of the uncertainty should be ascertained from the pathologist. If the suspicion of dysplasia is high (i.e., probably positive), short-term rebiopsy within 3–6 months or less may be indicated; if low (i.e., probably negative), the interval should be reduced to every 6–12 months.
Obtain 4 biopsy specimens of flat mucosa every 10 cm (consider sampling every 5 cm in the rectosigmoid).
Place each quadruplicate set in a separate specimen jar (as opposed to pooling biopsy specimens from several colonic segments).
Sample suspicious lesions or polyps.
Make sure to biopsy flat mucosa around the base of any suspicious polyp and submit specimen in a separate container.
In Crohn’s colitis, strictures may require using a thinner caliber colonoscope.
Consider brush cytology or barium enema to evaluate impassable strictures.

Modified from: Itzkowitz SH, Harpaz N. Diagnosis and management of dysplasia in patients with inflammatory bowel diseases. *Gastroenterology*. 2004;126(6):1634-48.

References:

1. **Eaden J.** Review article: colorectal carcinoma and inflammatory bowel disease. *Aliment Pharmacol Ther.* 2004;20 Suppl 4:24-30.
2. **Eaden JA, Mayberry JF.** Colorectal cancer complicating ulcerative colitis: a review. *Am J Gastroenterol.* 2000;95(10):2710-9.
3. **Loftus EV, Jr.** Epidemiology and risk factors for colorectal dysplasia and cancer in ulcerative colitis. *Gastroenterol Clin North Am.* 2006;35(3):517-31.
4. **Bernstein CN, Blanchard JF, Kliever E, Wajda A.** Cancer risk in patients with inflammatory bowel disease: a population-based study. *Cancer.* 2001;91(4):854-62.
5. **Jess T, Loftus EV, Jr., Velayos FS, et al.** Risk of intestinal cancer in inflammatory bowel disease: a population-based study from olmsted county, Minnesota. *Gastroenterology.* 2006;130(4):1039-46.
6. **Friedman S, Rubin PH, Bodian C, Harpaz N, Present DH.** Screening and surveillance colonoscopy in chronic Crohn's colitis: results of a surveillance program spanning 25 years. *Clin Gastroenterol Hepatol.* 2008;6(9):993-8; quiz 953-4.
7. **Rubin DT, Turner JR.** Surveillance of dysplasia in inflammatory bowel disease: The gastroenterologist-pathologist partnership. *Clin Gastroenterol Hepatol.* 2006;4(11):1309-13.
8. **Rex DK, Bond JH, Winawer S, et al.** Quality in the technical performance of colonoscopy and the continuous quality improvement process for colonoscopy: recommendations of the U.S. Multi-Society Task Force on Colorectal Cancer. *Am J Gastroenterol.* 2002;97(6):1296-308.
9. **Itzkowitz SH, Harpaz N.** Diagnosis and management of dysplasia in patients with inflammatory bowel diseases. *Gastroenterology.* 2004;126(6):1634-48.
10. **Gupta RB, Harpaz N, Itzkowitz S, et al.** Histologic inflammation is a risk factor for progression to colorectal neoplasia in ulcerative colitis: a cohort study. *Gastroenterology.* 2007;133(4):1099-105; quiz 1340-1.
11. **Rutter M, Saunders B, Wilkinson K, et al.** Severity of inflammation is a risk factor for colorectal neoplasia in ulcerative colitis. *Gastroenterology.* 2004;126(2):451-9.
12. **Rutter MD, Saunders BP, Wilkinson KH, et al.** Cancer surveillance in longstanding ulcerative colitis: endoscopic appearances help predict cancer risk. *Gut.* 2004;53(12):1813-6.
13. **Collins PD, Mpfu C, Watson AJ, Rhodes JM.** Strategies for detecting colon cancer and/or dysplasia in patients with inflammatory bowel disease. *Cochrane Database Syst Rev.* 2006(2):CD000279.
14. **Itzkowitz SH, Present DH.** Consensus conference: Colorectal cancer screening and surveillance in inflammatory bowel disease. *Inflamm Bowel Dis.* 2005;11(3):314-21.
15. **Eaden JA, Mayberry JF.** Guidelines for screening and surveillance of asymptomatic colorectal cancer in patients with inflammatory bowel disease. *Gut.* 2002;51 Suppl 5:V10-2.
16. **Winawer S, Fletcher R, Rex D, et al.** Colorectal cancer screening and surveillance: clinical guidelines and rationale-Update based on new evidence. *Gastroenterology.* 2003;124(2):544-60.
17. **Bernstein CN, Weinstein WM, Levine DS, Shanahan F.** Physicians' perceptions of dysplasia and approaches to surveillance colonoscopy in ulcerative colitis. *Am J Gastroenterol.* 1995;90(12):2106-14.

18. **Eaden JA, Ward BA, Mayberry JF.** How gastroenterologists screen for colonic cancer in ulcerative colitis: an analysis of performance. *Gastrointest Endosc.* 2000;51(2):123-8.
19. **Rodriguez SA, Eisen GM.** Surveillance and management of dysplasia in ulcerative colitis by U.S. gastroenterologists: in truth, a good performance. *Gastrointest Endosc.* 2007;66(5):1070.
20. **Rubin CE, Haggitt RC, Burner GC, et al.** DNA aneuploidy in colonic biopsies predicts future development of dysplasia in ulcerative colitis. *Gastroenterology.* 1992;103(5):1611-20.
21. **Riddell RH, Goldman H, Ransohoff DF, et al.** Dysplasia in inflammatory bowel disease: standardized classification with provisional clinical applications. *Hum Pathol.* 1983;14(11):931-68.
22. **Dixon MF, Brown LJ, Gilmour HM, et al.** Observer variation in the assessment of dysplasia in ulcerative colitis. *Histopathology.* 1988;13(4):385-97.
23. **Melville DM, Jass JR, Morson BC, et al.** Observer study of the grading of dysplasia in ulcerative colitis: comparison with clinical outcome. *Hum Pathol.* 1989;20(10):1008-14.
24. **Odze RD, Goldblum J, Noffsinger A, Alsaigh N, Rybicki LA, Fogt F.** Interobserver variability in the diagnosis of ulcerative colitis-associated dysplasia by telepathology. *Mod Pathol.* 2002;15(4):379-86.
25. **Odze RD, Tomaszewski JE, Furth EE, et al.** Variability in the diagnosis of dysplasia in ulcerative colitis by dynamic telepathology. *Oncol Rep.* 2006;16(5):1123-9.
26. **Bernstein CN, Shanahan F, Weinstein WM.** Are we telling patients the truth about surveillance colonoscopy in ulcerative colitis? *Lancet.* 1994;343(8889):71-4.
27. **Rutter MD, Saunders BP, Wilkinson KH, et al.** Thirty-year analysis of a colonoscopic surveillance program for neoplasia in ulcerative colitis. *Gastroenterology.* 2006;130(4):1030-8.
28. **Befrits R, Ljung T, Jaramillo E, Rubio C.** Low-grade dysplasia in extensive, long-standing inflammatory bowel disease: a follow-up study. *Dis Colon Rectum.* 2002;45(5):615-20.
29. **Lim CH, Dixon MF, Vail A, Forman D, Lynch DA, Axon AT.** Ten year follow up of ulcerative colitis patients with and without low grade dysplasia. *Gut.* 2003;52(8):1127-32.
30. **Ullman TA, Loftus EV, Jr., Kakar S, Burgart LJ, Sandborn WJ, Tremaine WJ.** The fate of low grade dysplasia in ulcerative colitis. *Am J Gastroenterol.* 2002;97(4):922-7.
31. **Ullman T, Croog V, Harpaz N, Sachar D, Itzkowitz S.** Progression of flat low-grade dysplasia to advanced neoplasia in patients with ulcerative colitis. *Gastroenterology.* 2003;125(5):1311-9.
32. **Bernstein CN.** Ulcerative colitis with low-grade dysplasia. *Gastroenterology.* 2004;127(3):950-6.
33. **Thomas T, Abrams KA, Robinson RJ, Mayberry JF.** Meta-analysis: cancer risk of low-grade dysplasia in chronic ulcerative colitis. *Aliment Pharmacol Ther.* 2007;25(6):657-68.
34. **Ullman T, Croog V, Harpaz N, et al.** Progression to colorectal neoplasia in ulcerative colitis: effect of mesalamine. *Clin Gastroenterol Hepatol.* 2008;6(11):1225-30; quiz 1177.
35. **Blonski W, Kundu R, Lewis J, Aberra F, Osterman M, Lichtenstein GR.** Is dysplasia visible during surveillance colonoscopy in patients with ulcerative colitis? *Scand J Gastroenterol.* 2008;43(6):698-703.

36. **Rubin DT, Rothe JA, Hetzel JT, Cohen RD, Hanauer SB.** Are dysplasia and colorectal cancer endoscopically visible in patients with ulcerative colitis? *Gastrointest Endosc.* 2007;65(7):998-1004.
37. **Rutter MD, Saunders BP, Wilkinson KH, Kamm MA, Williams CB, Forbes A.** Most dysplasia in ulcerative colitis is visible at colonoscopy. *Gastrointest Endosc.* 2004;60(3):334-9.
38. **Blackstone MO, Riddell RH, Rogers BH, Levin B.** Dysplasia-associated lesion or mass (DALM) detected by colonoscopy in long-standing ulcerative colitis: an indication for colectomy. *Gastroenterology.* 1981;80(2):366-74.
39. **Nugent FW, Haggitt RC, Gilpin PA.** Cancer surveillance in ulcerative colitis. *Gastroenterology.* 1991;100(5 Pt 1):1241-8.
40. **Connell WR, Lennard-Jones JE, Williams CB, Talbot IC, Price AB, Wilkinson KH.** Factors affecting the outcome of endoscopic surveillance for cancer in ulcerative colitis. *Gastroenterology.* 1994;107(4):934-44.
41. **Medlicott SA, Jewell LD, Price L, Fedorak RN, Sherbaniuk RW, Urbanski SJ.** Conservative management of small adenomata in ulcerative colitis. *Am J Gastroenterol.* 1997;92(11):2094-8.
42. **Odze RD.** Adenomas and adenoma-like DALMs in chronic ulcerative colitis: a clinical, pathological, and molecular review. *Am J Gastroenterol.* 1999;94(7):1746-50.
43. **Engelsgjerd M, Farraye FA, Odze RD.** Polypectomy may be adequate treatment for adenoma-like dysplastic lesions in chronic ulcerative colitis. *Gastroenterology.* 1999;117(6):1288-94; discussion 1488-91.
44. **Odze RD, Farraye FA, Hecht JL, Hornick JL.** Long-term follow-up after polypectomy treatment for adenoma-like dysplastic lesions in ulcerative colitis. *Clin Gastroenterol Hepatol.* 2004;2(7):534-41.
45. **Rubin PH, Friedman S, Harpaz N, et al.** Colonoscopic polypectomy in chronic colitis: conservative management after endoscopic resection of dysplastic polyps. *Gastroenterology.* 1999;117(6):1295-300.
46. **Friedman S, Odze RD, Farraye FA.** Management of neoplastic polyps in inflammatory bowel disease. *Inflamm Bowel Dis.* 2003;9(4):260-6.
47. **Vieth M, Behrens H, Stolte M.** Sporadic adenoma in ulcerative colitis: endoscopic resection is an adequate treatment. *Gut.* 2006;55(8):1151-5.
48. **Ullman T, Odze R, Farraye FA.** Diagnosis and management of dysplasia in patients with ulcerative colitis and Crohn's disease of the colon. *Inflamm Bowel Dis.* 2008.
49. **Blonski W, Kundu R, Furth EF, Lewis J, Aberra F, Lichtenstein GR.** High-grade dysplastic adenoma-like mass lesions are not an indication for colectomy in patients with ulcerative colitis. *Scand J Gastroenterol.* 2008;43(7):817-20.
50. **Farraye FA, Waye JD, Moscandrew M, Heeren TC, Odze RD.** Variability in the diagnosis and management of adenoma-like and non-adenoma-like dysplasia-associated lesions or masses in inflammatory bowel disease: an Internet-based study. *Gastrointest Endosc.* 2007;66(3):519-29.
51. **Rutter M, Bernstein C, Matsumoto T, Kiesslich R, Neurath M.** Endoscopic appearance of dysplasia in ulcerative colitis and the role of staining. *Endoscopy.* 2004;36(12):1109-14.
52. **Farraye FA, Schroy PC, 3rd.** Chromoendoscopy: a new vision for colonoscopic surveillance in IBD. *Gastroenterology.* 2006;131(1):323-5; discussion 325-6.
53. **Thorlacius H, Toth E.** Role of chromoendoscopy in colon cancer surveillance in inflammatory bowel disease. *Inflamm Bowel Dis.* 2007;13(7):911-7.

54. **Kiesslich R, Galle PR, Neurath MF.** Endoscopic surveillance in ulcerative colitis: smart biopsies do it better. *Gastroenterology*. 2007;133(3):742-5.
55. **Hurlstone DP, Sanders DS, Lobo AJ, McAlindon ME, Cross SS.** Indigo carmine-assisted high-magnification chromoscopic colonoscopy for the detection and characterisation of intraepithelial neoplasia in ulcerative colitis: a prospective evaluation. *Endoscopy*. 2005;37(12):1186-92.
56. **Marion JF, Waye JD, Present DH, et al.** Chromoendoscopy-targeted biopsies are superior to standard colonoscopic surveillance for detecting dysplasia in inflammatory bowel disease patients: a prospective endoscopic trial. *Am J Gastroenterol*. 2008;103(9):2342-9.
57. **Kiesslich R, Fritsch J, Holtmann M, et al.** Methylene blue-aided chromoendoscopy for the detection of intraepithelial neoplasia and colon cancer in ulcerative colitis. *Gastroenterology*. 2003;124(4):880-8.
58. **Rutter MD, Saunders BP, Schofield G, Forbes A, Price AB, Talbot IC.** Pancolonic indigo carmine dye spraying for the detection of dysplasia in ulcerative colitis. *Gut*. 2004;53(2):256-60.
59. **Matsumoto T, Iwao Y, Igarashi M, et al.** Endoscopic and chromoendoscopic atlas featuring dysplastic lesions in surveillance colonoscopy for patients with long-standing ulcerative colitis. *Inflamm Bowel Dis*. 2008;14(2):259-64.
60. **Hurlstone DP, Brown S.** Techniques for targeting screening in ulcerative colitis. *Postgrad Med J*. 2007;83(981):451-60.
61. **Dekker E, van den Broek FJ, Reitsma JB, et al.** Narrow-band imaging compared with conventional colonoscopy for the detection of dysplasia in patients with longstanding ulcerative colitis. *Endoscopy*. 2007;39(3):216-21.
62. **Matsumoto T, Kudo T, Jo Y, Esaki M, Yao T, Iida M.** Magnifying colonoscopy with narrow band imaging system for the diagnosis of dysplasia in ulcerative colitis: a pilot study. *Gastrointest Endosc*. 2007;66(5):957-65.
63. **Hoffman A, Goetz M, Vieth M, Galle PR, Neurath MF, Kiesslich R.** Confocal laser endomicroscopy: technical status and current indications. *Endoscopy*. 2006;38(12):1275-83.
64. **Hurlstone DP, Thomson M, Brown S, Tiffin N, Cross SS, Hunter MD.** Confocal endomicroscopy in ulcerative colitis: differentiating dysplasia-associated lesion mass and adenoma-like mass. *Clin Gastroenterol Hepatol*. 2007;5(10):1235-41.
65. **Kiesslich R, Goetz M, Lammersdorf K, et al.** Chromoscopy-guided endomicroscopy increases the diagnostic yield of intraepithelial neoplasia in ulcerative colitis. *Gastroenterology*. 2007;132(3):874-82.
66. **Hurlstone DP, Kiesslich R, Thomson M, Atkinson R, Cross SS.** Confocal chromoscopic endomicroscopy is superior to chromoscopy alone for the detection and characterisation of intraepithelial neoplasia in chronic ulcerative colitis. *Gut*. 2008;57(2):196-204.
67. **Chen R, Rabinovitch PS, Crispin DA, et al.** DNA fingerprinting abnormalities can distinguish ulcerative colitis patients with dysplasia and cancer from those who are dysplasia/cancer-free. *Am J Pathol*. 2003;162(2):665-72.
68. **Tahara T, Inoue N, Hisamatsu T, et al.** Clinical significance of microsatellite instability in the inflamed mucosa for the prediction of colonic neoplasms in patients with ulcerative colitis. *J Gastroenterol Hepatol*. 2005;20(5):710-5.

69. **Gitin Y, Farraye FA, Zhang X, Liu G, Spira A, Brody JS.** Evaluation of global gene expression in rectal mucosa obtained by a non-invasive technique in patients with ulcerative colitis. *Gastroenterology*. 2008;134:S237.
70. **Farraye FA, Andrews CW, Shah SA, et al.** Analysis of DNA mutations in stool is a novel method to detect neoplasia in patients with inflammatory bowel disease. *Am J Gastroenterol*. 2005;100(S302).
71. **Itzkowitz S, Jandorf L, Ullman T, et al.** Stool DNA testing identifies patients with inflammatory bowel disease and dysplasia. *Gastroenterology*. 2005;128:A567.
72. **Lashner BA, Heidenreich PA, Su GL, Kane SV, Hanauer SB.** Effect of folate supplementation on the incidence of dysplasia and cancer in chronic ulcerative colitis. A case-control study. *Gastroenterology*. 1989;97(2):255-9.
73. **Lashner BA, Provencher KS, Seidner DL, Knesebeck A, Brzezinski A.** The effect of folic acid supplementation on the risk for cancer or dysplasia in ulcerative colitis. *Gastroenterology*. 1997;112(1):29-32.
74. **Tung BY, Emond MJ, Haggitt RC, et al.** Ursodiol use is associated with lower prevalence of colonic neoplasia in patients with ulcerative colitis and primary sclerosing cholangitis. *Ann Intern Med*. 2001;134(2):89-95.
75. **Pardi DS, Loftus EV, Jr., Kremers WK, Keach J, Lindor KD.** Ursodeoxycholic acid as a chemopreventive agent in patients with ulcerative colitis and primary sclerosing cholangitis. *Gastroenterology*. 2003;124(4):889-93.
76. **Bansal P, Sonnenberg A.** Risk factors of colorectal cancer in inflammatory bowel disease. *Am J Gastroenterol*. 1996;91(1):44-8.
77. **Rubin DT, LoSavio A, Yadron N, Huo D, Hanauer SB.** Aminosalicylate therapy in the prevention of dysplasia and colorectal cancer in ulcerative colitis. *Clin Gastroenterol Hepatol*. 2006;4(11):1346-50.
78. **Velayos FS, Terdiman JP, Walsh JM.** Effect of 5-aminosalicylate use on colorectal cancer and dysplasia risk: a systematic review and metaanalysis of observational studies. *Am J Gastroenterol*. 2005;100(6):1345-53.
79. **Rubin DT, Cruz-Correa MR, Gasche C, et al.** Colorectal cancer prevention in inflammatory bowel disease and the role of 5-aminosalicylic acid: A clinical review and update. *Inflamm Bowel Dis*. 2008;14(2):265-74.
80. **Chan EP, Lichtenstein GR.** Chemoprevention: risk reduction with medical therapy of inflammatory bowel disease. *Gastroenterol Clin North Am*. 2006;35(3):675-712.
81. **Levine JS, Burakoff R.** Chemoprophylaxis of colorectal cancer in inflammatory bowel disease: current concepts. *Inflamm Bowel Dis*. 2007;13(10):1293-8.