

CURRENT ISSUES IN GI POLYP PATHOLOGY

Moderator: Wendy Frankel
The Ohio State University, Columbus, OH

Agenda:

- 1:30 **Diagnosis and management of polyps in IBD**
Robert D. Odze, Brigham and Women's Hospital and Harvard Medical School,
Boston, MA
- 2:05 **Adenocarcinoma in colonic adenomas: Diagnosis and management**
Mary P. Bronner, The Cleveland Clinic Foundation, Cleveland, OH
- 2:40 **Polyps with no names or with obscure names**
Henry D. Appelman, The University of Michigan, Ann Arbor, MI
- 3:15 BREAK
- 3:45 **Serrated colorectal polyps: New challenges to old dogma**
Kenneth P. Batts, Abbott Northwestern Hospital, Minneapolis MN
- ROGER C. HAGGITT MEMORIAL LECTURE*
- 4:20 **Gastric lumps and bumps: No polyp is an island**
Robert M. Genta, Universite de Geneve, Switzerland

*Sponsored by a generous contribution from Axcan Pharma, Inc.

Diagnosis and Management of Polyps in Inflammatory Bowel Disease

Robert D. Odze, M.D., F.R.C.P.C.
Chief, GI Pathology Service
Associate Professor of Pathology
Brigham & Women's Hospital
Harvard Medical School
Boston, MA

Introduction

The majority of polyps in inflammatory bowel disease (IBD) are inflammatory. Hyperplastic, mesenchymal, lymphoid, and a variety of other polyps may also occur in IBD, but less commonly. However, most of the polyps in these other categories do not necessarily show an increased prevalence in IBD, but instead develop coincidentally in association with IBD. Epithelial polyps associated with IBD are mainly dysplastic, and as a result, pose a difficult diagnostic dilemma regarding their separation from sporadic neoplastic lesions. This lecture will concentrate mainly on lesions with an increased frequency in IBD.

Inflammatory Polyps

A. Usual Type

Inflammatory polyps (or “pseudopolyps”) are the most common type of polyp in IBD. They represent polypoid areas of inflamed and regenerating mucosa that project above the level of the surrounding mucosa, the latter of which may be ulcerated. They occur most commonly in patients with moderate to severe colitis, but persist in patients with quiescent disease, and may also occur in association with the other inflammatory disorders of the GI tract, such as ischemic colitis or infectious colitis¹⁻². Overall, they are believed to develop as a regenerative response to localized, or diffuse, inflammation and ulceration of the mucosa followed by regeneration of the intervening non-ulcerated epithelium. Eventually, the regenerated mucosa becomes completely re-epithelialized and persists above the level of the surrounding mucosa, even when the latter has healed completely. However, some inflammatory polyps may simply represent residual islands of spared mucosa surrounding areas of deep ulceration, and it is these types of lesions that have been referred to as “pseudopolyps” by some.

Grossly, inflammatory polyps may be sessile or pedunculated but may assume almost any shape. For instance, some may be worm-like or consist of long finger-like projections, often referred to as filiform³⁻⁴. They may be single, multiple or numerous in number, and usually range in size from 0.5 to 1.0 cm. However, some polyps may grow to an extremely large size (“giant” inflammatory polyp), which can result in bleeding, obstruction, prolapse or intussusception⁵⁻⁹. Endoscopically, most inflammatory polyps

have a smooth hyperemic/hypervascular appearance with or without surface erosion, and tend to bleed when manipulated. Their appearance is usually easily distinguishable from neoplastic polyps. Histologically, inflammatory polyps are composed of a mixture of inflamed lamina propria and distorted colonic epithelium consisting of tortuous, branched, elongated and cystic crypts. Surface erosion, congestion, hemorrhage, and crypt abscesses may also be present.

The vast majority of inflammatory polyps are benign, innocuous lesions, which do not cause any significant complications. Occasionally, as mentioned above, particularly in severe cases of IBD, numerous inflammatory polyps with long finger-like projections (filliform polyposis), may develop, particularly in the distal colorectum, and cause obstructive symptoms^{3,4,8}. The main clinical issue in patients with filliform polyposis is the difficulty in monitoring their progression, separating purely inflammatory ones from those with dysplasia, and performing regular biopsy surveillance. As a result, most patients with extensive filliform polyposis are treated by colectomy. Some inflammatory polyps develop markedly enlarged, spindle or epithelioid shaped, multi nucleated, bizarre stromal cells that mimic sarcoma. These are referred to as pseudosarcomatous changes, and occur most often at the surface of the polyp, particularly in those that are ulcerated¹⁰. These cells can be distinguished from sarcoma by the lack of atypical mitoses, their location preferentially underneath areas of ulceration within a granulation tissue reaction, and their frequent positivity for endothelial, or myofibroblast, phenotypic markers.

Rarely, dysplasia or even carcinoma, may develop in inflammatory polyps¹¹⁻¹². The histologic features are similar to dysplasia or carcinoma that develops in flat mucosa in IBD. However, inflammatory polyps do not carry a significantly increased risk of dysplasia above that of the surrounding mucosa, and, thus, are not considered pre-neoplastic lesions.

The natural history of inflammatory polyps is unclear. Some polyps decrease in size, most remain stable and few may continue to grow, particularly if they undergo torsion or prolapse. Treatment is generally directed at the underlying inflammatory condition. However, large, or numerous, polyps are often excised to rule out dysplasia. Inflammatory polyps with dysplasia should be managed similar to dysplasia in flat mucosa.

B. Inflammatory Cap Polyps

Some inflammatory polyps in IBD may develop either primarily, or secondarily, as a result of peristalsis or trauma induced mucosal prolapse¹³⁻¹⁶. This may result in traction, distortion and twisting of the polyp which can lead to localized ischemic damage, regeneration and repair of the lamina propria and epithelium and the development of an inflammatory polyp. Cap polyps are defined as an inflammatory polyp, either with or without prolapse-related changes, that contain an overlying “cap” of necroinflammatory debris and granulation tissue¹⁴. Cap polyps are usually isolated lesions, but they can be numerous in number which can lead to bleeding, obstruction, or rarely, hypoproteinemia^{9,14,16}. Most cap polyps occur in the rectosigmoid region on the crest of

mucosal folds. Most are less than 1.0 cm in size. Other types of mucosal prolapse polyps, without a cap of granulation tissue, may also develop in IBD, but are less common.

C. Colitis Cystica Polyposa/Profunda

This is a rare benign condition characterized by misplacement of mature, often architecturally distorted or cystically dilated, crypts through the muscularis mucosa into the submucosa or deep layers of the bowel wall¹⁷⁻¹⁹. This condition occurs more commonly in patients with solitary rectal ulcer syndrome, but may also occur, rarely, in patients with IBD, particularly Crohn's disease. In IBD, colitis cystica polyposa/profunda (CCP) may be either localized or diffuse. The pathogenesis of CCP in IBD is believed to occur as a result of repeated bouts of ulceration followed by repair of the mucosa and entrapment of epithelium. Histologically, in addition to the typical features of IBD in the overlying and surrounding mucosa, CCP may show cystically dilated, architecturally distorted, mucin-filled crypts in the submucosa, muscularis propria, or serosa¹⁹. The crypts may be entirely normal in appearance or may show marked regenerative changes which, on occasion, may be difficult to distinguish from well-differentiated adenocarcinoma. However, in contrast to adenocarcinoma, misplaced crypts in CCP often grow in a lobular configuration, are not associated with desmoplasia, and are often surrounded by a discrete rim of lamina propria. Misplaced crypts may also show mucin depletion, pseudostratification, and hyperchromaticity of the nuclei. However, loss of polarity, atypical mitoses, and intraluminal necrosis are not features of this disorder. Some cases may show extensive hemorrhage, congestion and hemosiderin deposition. The treatment of CCP depends primarily on the mode of clinical presentation. Most cases are resected due to the difficulty in distinguishing this condition from carcinoma from a clinical, radiological or pathological point of view, or because of intraluminal obstruction. IBD-related CCP does not carry an increased risk of neoplastic change.

Hyperplastic polyps

Hyperplastic polyps may occur in patients with IBD and are usually morphologically similar to those that occur in non-IBD patients²¹. They may occur in inflamed or normal appearing mucosa. In a study by our group, the molecular characteristics of 39 hyperplastic polyps from 26 ulcerative colitis (UC) patients were compared to 39 sporadic hyperplastic polyps from patients without UC²¹. Most polyps (92%) were located within an area of established colitis, and in the left colon (82%). Polyps ranged in size from 0.1-1.4 cm in diameter (average: 4.3 mm). Forty-seven percent of UC-associated hyperplastic polyps showed a molecular abnormality, such as LOH of APC (21%), 3p (40%), p53 (27%), or p16 (20%). However, the frequency of molecular abnormalities was similar to sporadic hyperplastic polyps, which suggested that UC-associated hyperplastic polyps are biologically similar to the sporadic type. Nevertheless, the finding of molecular abnormalities in these lesions supports the theory that these lesions may have neoplastic potential which is probably unrelated to the

underlying IBD. Interestingly, non-polypoid flat hyperplasia-like mucosal changes has also recently been described in Crohn's disease by Kilgore et al²². In a morphological and p53 immunohistochemical study of 30 cases of Crohn's-related adenocarcinoma and 38 age and sex matched cases of Crohn's disease without adenocarcinoma, hyperplastic mucosal changes were present in 33% of the former and 10% of the latter. These changes were characterized by a "diffuse expanse of flat mucosa with an architecture resembling that seen in colorectal hyperplastic polyps and composed of cells with cytologically bland basal nuclei and apical cytoplasmic mucin distention". These features were noted both adjacent to and distant from adenocarcinoma. Fifty percent of cases showed p53 immunoreactivity. The authors of that study suggested that this may represent a distinct type of dysplastic change, but this is yet to be confirmed. A similar type of "villous mucinous mucosa" has recently been described in long-standing UC by Anderson et al in 1999²³. These investigators showed a high frequency of K-ras mutations in this type of epithelium (61%), which was more frequent than low-grade dysplasia. However, it is unclear if the type of epithelium evaluated in the study by Anderson et al is the same as the one evaluated by Kilgore et al.

The natural history of hyperplastic polyps in IBD is unknown, and the treatment of these lesions is similar to patients without IBD. Clinically, hyperplastic polyps may be difficult to distinguish from small elevated polypoid areas of dysplasia and, thus, are often excised for diagnosis.

Epithelial

A. General comments and classification

Elevated or raised areas of dysplastic epithelium occurs, not uncommonly, in patients with IBD^{1,12,24}. By convention, raised dysplastic areas have been referred to as a dysplasia associated lesion or mass (DALM)¹². However, there are, in fact, several different subtypes of DALM's in IBD. These subtypes are broadly separated into adenoma-like and non-adenoma like based primarily on their gross endoscopic appearance, and are managed quite differently. Examples of non-adenoma like lesions are large, sessile, irregular masses, strictures or ill-defined nodules with a broad base. A biopsy finding of dysplasia, either low or high-grade, in a non-adenoma like DALM is usually an indication for colectomy because of the high probability of an associated adenocarcinoma. In fact, many studies have shown a carcinoma prevalence rate from 30-80% in patients with lesions of this kind^{12,24}. More commonly, isolated, well-circumscribed, sessile or pedunculated adenoma-like polypoid dysplastic lesions develop in patients with IBD. In this instance, the clinical differential diagnosis includes an adenoma-like DALM in UC, a lesion that is pathogenetically linked to the underlying inflammatory disorder, versus a sporadic adenoma, a lesion that occurs coincidentally in a patient with underlying IBD, but is unrelated to it from an etiologic point of view. This distinction is important because the former type of lesion is generally considered an indication for colectomy in medically fit patients, due to a high rate of progression to adenocarcinoma, whereas the latter is normally treated by a polypectomy, similar to a

sporadic adenoma in a patient without IBD. Thus, a common diagnostic dilemma for both clinicians and pathologists is how to differentiate these lesions. Fortunately, recent data, primarily based on the results of two follow-up studies, suggests that IBD patients with an adenoma-like DALM, regardless of whether it is determined to represent a sporadic or an IBD related lesion, may be treated adequately by polypectomy and continued surveillance if there is no evidence of flat dysplasia elsewhere in the patient^{25,26}. This is discussed further below. Nevertheless, there are a variety of features that can be used to help distinguish these lesions, which are outlined in the next section.

B. Pathologic features and differential diagnosis

Non-adenoma like and adenoma-like DALM's may look identical histologically. Therefore, distinction between these two types of lesions is based solely on their gross endoscopic appearance and will not be discussed further. Adenoma-like lesions that occur proximal to histologic areas of colitis (i.e. right sided lesion in a patient with left sided UC) can easily be diagnosed as a sporadic adenoma because it is well known that dysplasia related to IBD develops only in areas involved by the inflammatory process. However, adenoma-like lesions that occur within areas of colitis are more difficult to distinguish from true polypoid dysplastic lesions related to the underlying colitis^{27,28}. IBD-associated lesions generally occur in younger patients (usually less than 60 years of age), with pancolitis for at least 10 years duration²⁷. These polyps are located more commonly in the left colon and are often associated with areas of flat dysplasia either near or distant from the polyp. Histologically, IBD-related lesions usually show an increase in the amount of lamina propria and crypt inflammation, and may even show crypt abscess's involving dysplastic epithelium. In a previous study by our group, a mixture of benign dysplastic inflamed crypts at the surface of the polyp was found more commonly (60% of cases) in IBD related lesions in contrast to sporadic adenomas (16%)²⁷. In addition, flat dysplasia is often detected at the base of the polyp stalk, and in the mucosa surrounding the polyp. Thus, stalk dysplasia should alert the pathologist that the polyp is likely to be an IBD-associated lesion, rather than a sporadic adenoma, and should prompt a search for dysplasia elsewhere in the colon. Features such as polyp size, architectural type, and degree of dysplasia, as well as nuclear cytologic features, are not helpful in distinguishing these two groups of lesions. Interestingly, one recent study by Rubio et al suggested that the majority of "adenomatous growths" juxtaposing IBD-associated carcinomas have a villous or serrated morphologic growth pattern, but the significance of this finding is unclear.²⁹

By immunohistochemistry, IBD-associated adenoma-like DALM's have a higher degree of p53, and a lower degree of nuclear beta-catenin, staining in contrast to sporadic adenomas³⁰. Although several other studies have evaluated immunohistochemical findings in these two groups of lesions, none have shown to be particularly useful in this differential diagnosis^{31,32}. For instance, the expression of Glut-1, or hMLH1 and hMSH2, show a similar degree and type of staining in DALM's versus sporadic adenomas^{31,32}.

C. Molecular features

There are well known differences in the type, prevalence and timing of certain molecular events in the pathogenesis of IBD (particularly UC)-associated neoplasia compared to sporadic colon carcinogenesis^{12,21,24,33-34}. For instance, UC associated neoplasms demonstrate infrequent and late mutations in the APC and beta-catenin genes, but show frequent early abnormalities in the 3p, p53, p27, and p16 genes in comparison to sporadic adenomas. Based on this information, several investigators have evaluated and compared the molecular findings in DALM's, some of which included pathogenetically distinct groups of adenoma-like lesions, to sporadic adenomas in an effort to help distinguish these two types of lesions^{28,33-35}. For instance, Fogt et al showed that LOH for p16 (9p), 17p (p53) and 3p were statistically more common in adenoma-like polypoid dysplasia compared to sporadic adenomas³⁵. LOH of p16, 17p and 3p were present in 35%, 16% and 50% in the former compared to 0%, 10% and 0% of the latter, respectively. A study by our group, in 2000, evaluated LOH of 3p, APC and P16 by PCR analysis in 21 UC patients with an adenoma-like DALM, and compared the results to 8 UC patients with a non-adenoma like DALM, and 23 non-UC patients with a sporadic adenoma³⁴. Interestingly, adenoma-like DALM's in UC had a statistically similar molecular profile to sporadic adenomas. For instance, LOH of 3p, APC and p16 were noted in 25%, 30%, and 5% of UC-related adenoma-like DALM's compared to 5%, 33%, and 4% of non-UC related sporadic adenomas. Furthermore, lesions that occurred either within or outside areas of chronic colitis had a similar molecular profile. However, in contrast, non-adenoma like DALM's showed a significantly higher frequency of LOH of 3p and p16 (50% and 56%, respectively) indicating that, perhaps, a different pathogenetic molecular sequence of events occurs in adenoma-like versus non-adenoma like DALM's in UC. Thus, although subtle molecular differences may exist between IBD and non-IBD related lesions, at this point, distinguishing groups of DALM's by molecular analysis remains an investigational tool.

Recently, Selaru et al evaluated the ability of artificial neural networks (ANNs), based on complementary DNA (cDNA) microarray technology, to discriminate between IBD and non-IBD related cancers³⁶. Use of this technology correctly diagnosed 12 blinded samples (3 IBD cancers and 9 sporadic cancers) in a test set indicating that this methodology may have great potential to discriminate among different types of dysplastic lesions in the future. Unfortunately, this study did not compare adenoma-like lesions in IBD to sporadic adenomas.

D. Natural history and Treatment

There is recent strong evidence to suggest that adenoma-like DALMS, regardless of their particular etiology (i.e. whether they represent an IBD-related or a sporadic lesion) may be treated conservatively with polypectomy and continued endoscopic surveillance, instead of colectomy^{25,26,37}. In a study by our group of 24 UC patients all of whom had a polypectomy followed by surveillance for an adenoma-like DALM, 58% of patients developed further adenoma-like lesions upon 3.5 years of follow-up, but only 1 patient developed an isolated focus of low-grade dysplasia and none developed carcinoma²⁵. These results were strikingly similar to a control group of non-UC patients with a sporadic adenoma who had a statistically similar frequency of recurrent polyp formation

when treated in a same manner. In an abstract presented by our group at the current USCAP meeting, the same cohort of patients noted above were followed for a longer period of time (average: 8 years)³⁷. Although, overall, 62% developed further adenoma-like lesions, which, once again, was similar to the non-UC control group, no other patients developed flat dysplasia and only one patient (4%) developed adenocarcinoma 7.5 years after his/her initial polypectomy. Strikingly similar results were found by Rubin et al in a follow-up study of dysplastic polyps in 48 IBD patients with a mean of 4.1 years of follow-up²⁶. In their study, none of the patients developed dysplasia or carcinoma in flat mucosa upon surgical resection or follow-up colonoscopy. Based primarily on the results of these two studies, a preliminary management scheme for patients with adenoma-like and non-adenoma like DALM's in UC has been recommended (see Figure 1 for details). However, it is important to remember that the treatment plan outlined in Figure 1 depends heavily on the endoscopic appearance of the lesion in question, and is based on the premise that there is no evidence of flat dysplasia in other areas of the patients colon by colonoscopic biopsy analysis. Regardless of the presence of an adenoma-like dysplastic lesion, any IBD patient who has one or more areas of flat dysplasia should be considered a candidate for colectomy.

Mesenchymal Polyps

A wide variety of mesenchymal polyps have been reported, anecdotally, in both Crohn's disease and UC, but none have shown a predilection to occur with increased frequency in either of these two conditions³⁸⁻³⁹. The pathologic features of these lesions are similar to those that occur outside the setting of IBD and, thus, will not be described here. However, of the numerous types of lesions that have been described, inflammatory fibroid polyps are the most common⁴⁰. These lesions have been described in Crohn's disease and UC, as well as in continent ileo-anal pouches after colectomy. Another extremely rare form of mesenchymal polyp that has recently been described in Crohn's disease is nodular neuronal hyperplasia³⁹. This proliferation may occur as an isolated lesion, or in association with an inflammatory polyp. Finally, fibroepithelial polyps may occur in the perianal area in patients with Crohn's disease, and are believed to develop as a result of chronic repeated injury³⁸.

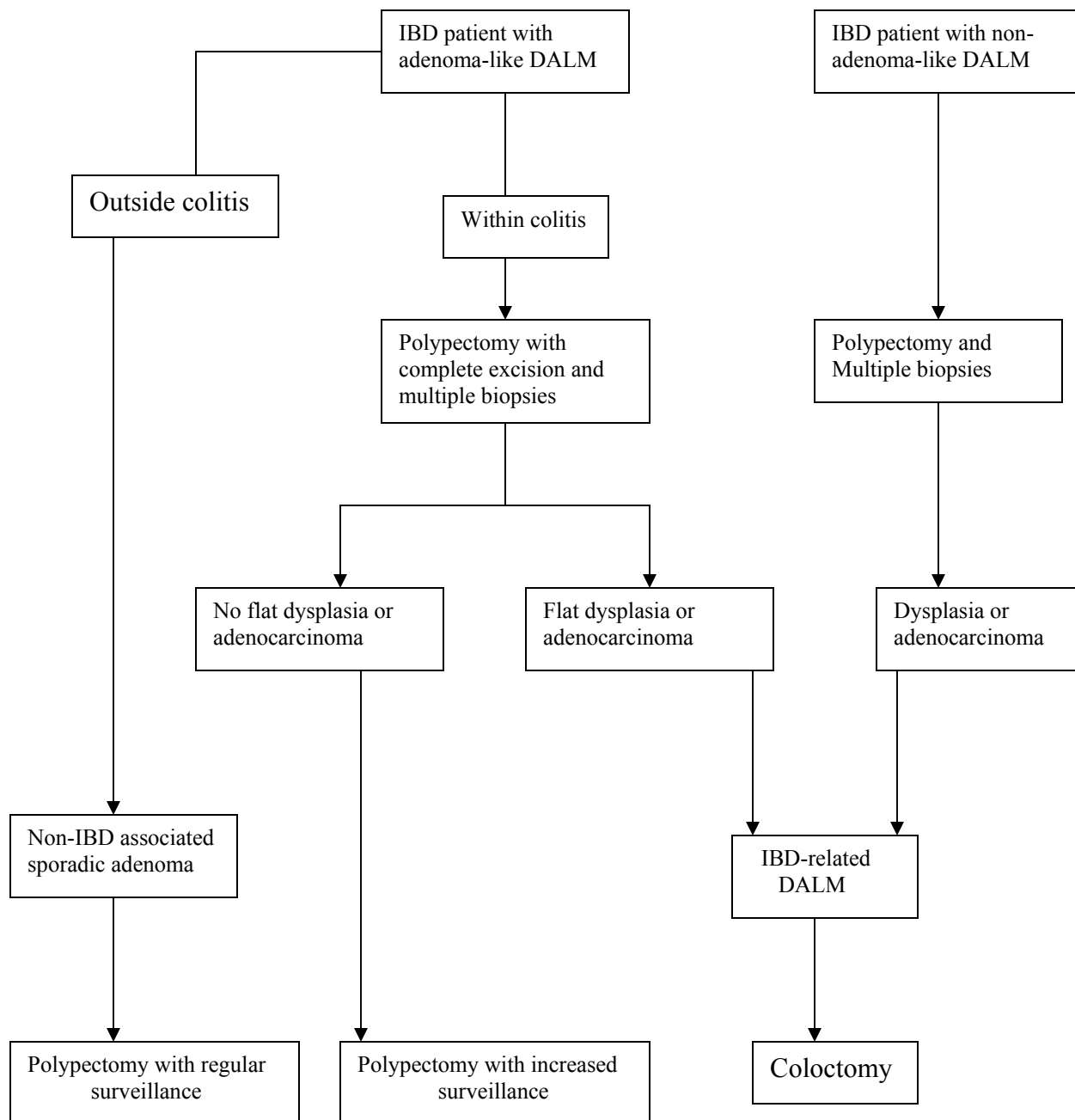
Lymphoid Polyps

Benign hyperplastic lymphoid nodules are, by far, the most common type of lymphoid polyp associated with IBD. Lymphoid hyperplasia is most common in the rectosigmoid region but may be particularly prominent, and diffuse, in segments of ileum or colon that have been diverted from the fecal stream, even in patients with IBD.

Non-Hodgkin's lymphoma is an extremely rare complication of IBD, but often presents as a polypoid lesion or mass⁴¹⁻⁴³. In one series of 117 GI lymphomas, only one arose in a patient with UC⁴³. However, in other studies, from 3-15% of colorectal lymphomas occur in UC patients⁴¹⁻⁴⁶. Although the association of lymphoma with IBD is

controversial, most authorities believe that the risk is slightly increased⁴⁷⁻⁵¹. The increase in risk may occur primarily, but is more likely due to the effects of immunosuppressive drugs, such as anti-TNF, azothiaprime, 6-MP and cyclosporin⁴⁷⁻⁵². In a recent report, the incidence of lymphoma was increased, and the interval to the development of lymphoma was decreased, in UC patients who were treated with immunosuppressive drugs compared to older reports⁵². Lymphomas associated with UC more commonly occur within the bowel, but may occur in surrounding lymphoid tissue as well. Within the bowel, they are almost always found in areas of active inflammation, are more often multiple, and occur more frequently in the distal colon, in contrast to non-IBD related GI lymphomas⁴⁵⁻⁴⁶. Histologically, they are often high grade, mostly of the diffuse large B cell type⁵². However, rare cases of low or high-grade polymorphic B cell lymphoma, marginal zone B cell lymphoma, and even T cell lymphoma, may occur as well^{42,46,53}.

Only a handful of lymphomas have been reported in Crohn's disease⁵². Rarely, primary intestinal Hodgkin's disease, some related to EB virus infection⁵², may develop in association with IBD, particularly Crohn's disease^{54,55}. Finally, some cases of malignant lymphoma of the colon may present with symptoms and signs simulating IBD, but in these cases, the affected patient does not actually have the inflammatory disorder⁵⁶⁻⁵⁷.

Figure 1. Treatment of DALMs in IBD

References

1. Levine DS, Surawicz CM, Spencer GD, et al. Inflammatory polyposis two years after ischemic colon injury. *Dig Dis Sci* 1986;31:1159-1167.
2. De Backer AI, Van Overbeke LN, Mortele KJ, et al: Inflammatory pseudopolyposis in a patient with toxic megacolon due to pseudomembranous colitis *JBR-BTR* 2001;84:201.
3. Bauknecht KJ, Grosse G, Kleinert J, Lachmann A, Niedobitek F. Filiform polyposis of the colon in chronic inflammatory bowel disease (so-called giant inflammatory polyps). *Zeitschrift fur Gastroenterologie* 2000;38(10):845-846.
4. Orławska J, Jarosz D, Bielecki K, Wejman J. Diffuse filiform polyposis of the colon in Crohn's disease. *Acta Pathol Microbiol Et Scan* 1996;104(2):94-98.
5. Ooi BS, Tjandra JJ, Pedersen JS, Bhathal PS. Giant pseudopolyposis in inflammatory bowel disease. *Australian & New Zealand Journal of Surgery* 2000;70(5):389-393.
6. Munchar J, Rahman HA, Zawawi MM. Localized giant pseudopolyposis in ulcerative colitis. *Eur J Gastroenterol Hepatol* 2001;13(11):1385-1387.
7. Ryu CB, Kwon KW, Kim JO, et al. Localized giant pseudopolyposis in Crohn's disease. *Gastroenterol Endoscop* 2002;55(7):914.
8. Okayama N, Itoh M, Yokoyama Y, et al. Total obliteration of colonic lumen by localized giant inflammatory polyposis in ulcerative colitis: report of a Japanese case. *Intern Med* 1996;35(1):24-29.
9. Anderson R, Kaariainen IT, Hanauer SB. Protein-losing enteropathy and massive pulmonary embolism in a patient with giant inflammatory polyposis and quiescent ulcerative colitis. *Am J Med* 1996;101(3):323-325.
10. Jessurun J, Paplanus SH, Nagle RB, et al. Pseudosarcomatous changes in inflammatory pseudopolyps of the colon. *Arch Pathol Lab Med* 1986;110:833-836.
11. Odze RD. Diagnostic problems and advances in inflammatory bowel disease. *Mod Pathol* 2003;16(4):347-458.
12. Odze RD. Adenomas and adenoma-like DALMs in chronic ulcerative colitis: a clinical, pathological, and molecular review. *Am J Gastroenterol* 1996;91:864-872.
13. Tendler DA, Aboudola S, Zacks JF, et al. Prolapsing mucosal polyps: an underrecognized form of colonic polyp-a clinicopathological study of 15 cases. *Am J Gastroenterol* 2002;97:370-376.
14. Tamura S, Onishi S, Ohkawauchi K, et al. A case of "cap polyposis"-like lesion associated with ulcerative colitis: is this a case of cap polyposis? *Am J Gastroenterol* 2000;95(11):3311-3312.
15. Oriuchi T, Kinouchi Y, Kimura M, et al. Successful treatment of cap polyposis by avoidance of intraluminal trauma: clues to pathogenesis. *Am J Gastroenterol* 2002;95:2095-2098.

16. Shiomi S, Moriyama Y, Oshitani N, et al. A case of cap polyposis investigated by scintigraphy with human serum albumin labeled with Tc-99m DTPA. *Clin Nucl Med* 1998;23:521-523.
17. Sakurai Y, Kabayashi H, Imazu H, et al. The development of an elevated lesion associated with colitis cystica profunda in the transverse colonic mucosa during the course of ulcerative colitis: report of a case. *Surgery Today* 2000;30(1):69-73.
18. Madan A, Minocha A. First reported case of colitis cystica profunda in association with Crohn's disease. *Am J Gastroenterol* 2002;97(9):2472-2473.
19. Guest CB, Reznick RK. Colitis cystica profunda; review of the literature. *Dis Colon Rectum* 1989;32:983-988.
20. Naganuma M, Iwao Y, Miura S, et al. A case of well differentiated adenocarcinoma with ulcerative colitis resembling colitis cystica profunda. *Japanese J Gastroenterol* 1999;96(6):658-663.
21. Odze RD, Brien T, Brown CA, et al. Molecular alterations in chronic ulcerative colitis-associated and sporadic hyperplastic polyps: a comparative analysis. *Am J Gastroenterol* 2002;97(9):1235-1242.
22. Kilgore SP, Sigel JE, Goldblum JR. Hyperplastic-like mucosal change in Crohn's disease: an unusual form of dysplasia? *Mod Pathol* 2000;13(7):797-801.
23. Andersen SN, Lovig T, Clausen OP, et al. Villous, hypermucinous mucosa in long standing ulcerative colitis shows high frequency of K-ras mutations. *Gut* 1999;45(5):686-892.
24. Friedman S, Odze RD, Farraye FA. Management of neoplastic polyps in inflammatory bowel disease. *Inflam Bowel Dis* 2003;9(4):260-266.
25. Engelsgjerd M, Farraye FA, Odze RD. Polypectomy may be adequate treatment for adenoma-like dysplastic lesions in chronic ulcerative colitis. *Gastroenterology* 1999;117:1288-1294.
26. Rubin PH. Adenomas in ulcerative colitis: endoscopic polypectomy or colectomy? *Inflam Bowel Dis* 1999;5(4):304-305.
27. Torres C, Antonioli D, Odze RD. Polypoid dysplasia and adenomas in inflammatory bowel disease. *Am J Surg Pathol* 1998;22(3):275-284.
28. Fogt F, Urbanski SJ, Sanders ME, et al. Distinction between dysplasia-associated lesion or mass (DALM) and adenoma in patients with ulcerative colitis. *Hum Pathol* 2000;31(3):288-291.
29. Rubio CA, Befrits R, Jaramillo E, et al. Villous and serrated adenomatous growth bordering carcinomas in inflammatory bowel disease. *Anticancer Res* 2000;20(6C):4761-4764.
30. Walsh SV, Loda M, Torres CM, et al. p53 and B-catenin expression in chronic ulcerative colitis-associated polypoid dysplasia and sporadic adenomas: an immunohistochemical study. *Am J Surg Pathol* 1999;23:963-969.
31. Fogt F, Wellmann A, Urbanski SJ, et al. Glut-1 expression in dysplastic and regenerative lesions of the colon. *Int J Mol Med* 2001;7(6):615-619.
32. Fogt F, Zimmerman RL, Poremba C, et al. Immunohistochemical screening of mismatch repair genes hMLH1, hMSH2, and hMSH6 in dysplastic lesions of the colon. *Appl Immunohistochem Mol Morphol* 2002;10(1):57-61.

33. Kern SE, Redston M, Seymour AB, et al. Molecular genetic profiles of colitis-associated neoplasms. *Gastroenterology* 1994;107:420-428.
34. Odze RD, Brown CA, Hartmann CJ, et al. Genetic alterations in chronic ulcerative colitis-associated adenoma-like DALMs are similar to non-colitic sporadic adenomas. *Am J Surg Pathol* 2000;24(9):1209-1216.
35. Fogt F, Vortmeyer AO, Goldman H, et al. Comparison of genetic alterations in colonic adenoma and ulcerative-colitis associated dysplasia and carcinoma. *Hum Pathol* 1998;29:131-136.
36. Seralu FM, Xu Y, Yin J, et al. Artificial neural networks distinguish among subtypes of neoplastic colorectal lesions. *Gastroenterology* 2002;122:606-613.
37. Hornick JL, Farraye FA, Hecht JL, Odze Rd. Long term outcome confirms that polypectomy is adequate treatment for adenoma-like DALM in ulcerative colitis. *USCAP* (2004)
38. Papiez JS, Hassenein A, Wilkinson E, Meynen CA. Recurrent atypical myxoid fibroepithelial polyp associated with vulvar Crohn's disease. *Int J Gyn Pathol* 2001;20(3):271-276.
39. Popiolek DA, Kahn E, Procaccino JA, et al. Nodular neuronal hyperplasia: a distinct morphologic type of pseudopolyp in inflammatory bowel disease. *Arch Pathol Lab Med* 1998;122(2):194-196.
40. Widgren S, Cox JN. Inflammatory fibroid polyp in a continent ileo-anal pouch after colectomy for ulcerative colitis – case report. *Pathol Res Pract* 1997;193(9):643-647.
41. Fan C-W, Changchien C, Wang J-Y, et al. Primary malignant lymphoma of the intestine: Clinicopathologic and immunohistochemical studies of 39 cases. *Pathol Int* 1995;45:123-130.
42. Shepherd N, Hall P, Coates P, et al. Primary malignant lymphoma of the colon and rectum. A histopathological and immunohistochemical analysis of 45 cases with clinicopathological correlations. *Histopathology* 1988;12:235-252.
43. Lewin K, Ranchod M, Dorfman R. Lymphomas of the gastrointestinal tract. *Cancer* 1978;42:693-707.
44. Loftus E, Tremaine W, Habermann T, et al. Risk of lymphoma in inflammatory bowel disease. *Am J Gastroenterol* 2000;95:2308-2312.
45. Wagonfeld J, Platz C, Fishman F, et al. Multicentric colonic lymphoma complicating ulcerative colitis. *Am J Dig Dis* 1977;22:502-508.
46. Lenzen R, Borchard F, Lubke H, et al. Colitis ulcerosa complicated by malignant lymphoma: case report and analysis of published works. *Gut* 1995;36:306-310.
47. Aiathal GP, Mansfield J. Review article: the risk of lymphoma associated with inflammatory bowel disease and immunosuppressive treatment. *Aliment Pharma Therapeutics* 2001;15(8):1101-1108.
48. Arseneau KO, Stukenborg GJ, Connors AF, et al. The incidence of lymphoid and myeloid malignancies among hospitalized Crohn's disease patients. *Inflam Bowel Dis*. 2001;7(2):106-112.
49. Khan S, Anderson GK, Eppstein AC, et al. Ulcerative colitis and colonic lymphoma: a theoretical link. *Am Surg* 2001;67(7):654-656.

50. Lewis JD, Schwartz JS, Lichtenstein GR. Azathioprine for maintenance of remission in Crohn's disease: benefits outweigh the risk of lymphoma. *Gastroenterology* 2000;118(6):1018-1024.
51. Bebb JR, Logan RP. Review article: does the use of immunosuppressive therapy in inflammatory bowel disease increase the risk of developing lymphoma? *Alim Pharm Therap* 2001;15(12):1843-1849.
52. Farrell R, Ang Y, Kileen P, et al. Increased incidence of non-Hodgkin's lymphoma in inflammatory bowel disease patients on immunosuppressive therapy but overall risk is low. *Gut* 2000;47:514-519.
53. Tsutsumi Y, Nakamura M, Machimura T. CD30-positive T cell lymphoma of the intestine, complicating ulcerative colitis. *Pathol Int* 1996;46(5):384-388.
54. Kelly MD, Stuart M, Tschuchnigg M, et al. Primary intestinal Hodgkin's disease complicating ileal Crohn's disease. *Aust N Z J surg* 1997;67(7):485-489.
55. Kumar S, Pruthi RK, Nichols WL. Perianal Hodgkin's lymphoma complicating Crohn's disease. *Int J Colorectal Dis* 2003;18(2):174-176.
56. Hurlston DP. Early phase mantle cell lymphoma: macroscopic similarities to terminal ileal Crohn's disease. *Am J Gastroenterol* 2002;97(9):1577-1578.
57. Ramasamy KA, Vignaraja R, Hastings AG, et al. A case of primary non-Hodgkin's lymphoma of the transverse colon presenting as inflammatory bowel disease. *Eur J Gastroenterol Hepatol* 2002;14(12):1401-1403.

ADENOCARCINOMA IN COLONIC ADENOMAS: DIAGNOSIS AND MANAGEMENT

Mary P. Bronner, MD
Cleveland Clinic Foundation

Carefully done autopsy studies have shown that the frequency of adenomas is approximately 50% for males and 40% for females in the United States.²⁰ Endoscopic series of colorectal adenomas generally report a lower prevalence of 20-30%.^{6,22} Either way, they are common. Endoscopically resected adenomas have an approximately 5% probability of containing a focus of adenocarcinoma upon histologic examination (Table 1).

TABLE 1: PREVALENCE OF CARCINOMA IN ADENOMAS

<i>Senior Author</i>	<i>Type of Study</i>	<i>% Adenomas with Carcinoma</i>
Muto ¹⁸	Surgical	11
Gillespie ⁶	Endoscopic	5
Shinya ²²	Endoscopic	5
Rickert ²⁰	Autopsy	1

The literature contains many references to villous adenomas having a higher “malignant potential” than tubular adenomas. Because the original source of this concept came from the world-renowned authority in gastrointestinal pathology, Dr. Basil C. Morson, it became dogma. Dr. Morson’s meaning was that a villous adenoma itself rather than the rest of the patient’s colon is more likely to harbor a focus of carcinoma than a tubular adenoma. Unfortunately, this concept of villous adenomas having a “higher malignant potential” has been misinterpreted to mean that these patients are more likely to have a colorectal carcinoma elsewhere in their colon or are more likely to develop one in their future. The composite literature provides no consensus. Table 2 summarizes data from six different studies analyzing factors that predict an increased risk of developing a future adenoma or carcinoma.

Grade of dysplasia and villous architecture, in particular, lack reproducibility as prognostic features. This relates at least in part to observer variability for these subjective aspects of adenomatous polyps. This further diminishes their utility. One study gained considerable attention regarding the prognostic utility of grade and villous change: that of Atkin et al. from the St. Marks Hospital in London published in the *New England Journal of Medicine*.¹ Their data were not confirmed by prior studies from the same institution (TABLE 2) and this discrepancy was not even mentioned in the Atkin study. Thus, even within one institution, grade and villous change are not reproducible prognostic factors. If anything, size in excess of one centimeter and multiplicity of adenomas are the only factors that seem to have achieved any degree of consensus as

predictors. Based on these data, neither routine grading of dysplasia in colonic adenomas nor their classification as tubular or villous is supported by the composite literature.

TABLE 2: PROGNOSTIC FACTORS FOR FUTURE ADENOMA/CARCINOMA

<i>Study</i>	<i>Age >60</i>	<i>Size >1cm</i>	<i>Villous or Tubular</i>	<i>Grade of Dysplasia</i>	<i>Number</i>
Morson, 1984 ¹⁶	NE	+	NE	NE	+
Neugut, 1985 ¹⁹	+	-	-	-	-
Lofti, 1986 ¹²	-	-	-	NE	+
Williams (St. Marks), 1986 ²⁶	+	+	-	-	+
Atkin (St. Marks), 1992 ¹	-	+	+	+	+
Natl. Polyp Study, 1993 ²⁸	+	+	-	-	+

NE = not evaluated

STEPS IN THE MANAGEMENT OF AN ENDOSCOPICALLY RESECTED ADENOMA CONTAINING CARCINOMA

Confirm the Diagnosis of Adenocarcinoma

The first and most important step in managing a patient with an endoscopically resected lesion is a correct diagnosis of invasive carcinoma. This may be challenging because “pseudo-carcinomatous” invasion, or misplaced epithelium within the submucosa or even deeper, is fairly common in colonic adenomas.^{7,17,23} This must be distinguished from adenocarcinoma invading the submucosa (Table 3). Misplaced epithelium is a benign phenomenon that most commonly occurs in large, pedunculated, sigmoid colonic polyps. It is clinically insignificant if the adenoma has been completely excised. In contrast, the presence of submucosal invasion is the diagnostic hallmark of colonic adenocarcinoma with its attendant risk of lymph node or distant metastasis.^{4,9,27} In the colon, in contrast to the esophagus and stomach, there is no risk of metastasis until carcinoma has invaded into the submucosa.^{4,9} Thus, intramucosal epithelial neoplasms of the colon are biologically benign. Because of this, most GI pathologists restrict the term “carcinoma” in the colon to lesions that have invaded into the submucosa. As advocated by the World Health Organization, the terms “carcinoma in-situ” and “intramucosal carcinoma” should be avoided. Use of this terminology in the colon may precipitate unwarranted colectomy for what are biologically benign lesions that are curable by complete endoscopic polypectomy alone. In addition, the diagnosis of carcinoma has strong psychological content for patients and may erroneously impact their insurability.

Regardless of these definitional issues for adenocarcinoma of the colon, it can frequently be challenging to distinguish between benign misplaced epithelium within the submucosa or deeper and adenocarcinoma invading the submucosa or deeper.^{7,17,23} The most useful histologic features in this differential are: 1) the rounded appearance of the glands on low power in benign, misplaced epithelium vs. the irregular, angulated and infiltrative appearance of invasive adenocarcinoma; and 2) the presence of lamina propria surrounding the dysplastic glands in misplaced epithelium vs. the characteristic

desmoplastic stroma that develops in response to submucosal invasion of colonic adenocarcinoma. This second feature is the more important criterion. Direct comparison of obvious benign lamina propria in a given polyp to any potential desmoplastic stroma may be very helpful. The appearance of lamina propria will vary from patient to patient and even from different colonic locations within the same patient, and so too will desmoplasia, so that direct internal comparison provides valuable information and in the great majority of cases will permit this distinction.

Both of the above listed features (glandular architecture and stroma) may be obscured by cautery artifact, inflammation, erosion and ulceration. The orderly and grouped appearance of the glands may be disrupted by these confounders, as may the nature of the surrounding stroma, which usually appears more cellular and desmoplastic-like with cautery or erosion/ulceration. An important aide to differentiating ulcer stroma from true desmoplasia is stromal vascularity. Ulcer stroma is granulation tissue composed in large part of capillaries. True desmoplasia on the other hand is usually hypovascular.

In addition to the above two main criteria in the differential of benign versus malignant, hemosiderin deposits and dense collagen tend to be common in association with benign misplaced epithelium and are very unusual if only invasive adenocarcinoma is present. Hemosiderin deposition and fibrosis are probably related to chronic trauma and torsion of the polyp stalk with associated hemorrhage and herniation of epithelium into the submucosa. Benign misplaced epithelium is most common in large, pedunculated sigmoid adenomas, probably because of the increased likelihood of stalk formation in and torsion of polyps from this region of the colon, due to the more solid nature of the stool here in comparison to the more proximal colon.

Benign misplaced epithelium, as well as invasive adenocarcinoma, may both be associated with acellular mucin pools within the submucosa (Table 3). As a practical rule, acellular mucin collections in these lesions have the same biologic significance as the associated epithelium. That is, if the associated epithelium consists of benign misplaced glands with accompanying lamina propria, then the mucin pools are also benign. If the associated epithelium is that of invasive adenocarcinoma, then the mucin pools should be regarded as part of the malignant process.^{5,7,9,17,23}

TABLE 3: CARCINOMA VERSUS BENIGN MISPLACED EPITHELIUM

<i>Feature</i>	<i>Misplaced Epithelium</i>	<i>Adenocarcinoma</i>
Lamina propria around glands	+	-
Desmoplasia around glands	-	+
Hemosiderin & dense fibrosis	+	-
Mucous lakes	+	+
High-grade dysplasia	+	+
Rounded low power appearance	+	-
Infiltrative low power appearance	-	+

Benign misplaced epithelium may develop in gastrointestinal tract pathologies other than adenomatous polyps. These include Peutz-Jeghers' polyps, inverted hyperplastic polyps, colitis cystica profunda in association with idiopathic inflammatory bowel disease or radiation-induced injury, solitary rectal ulcer syndrome, and other forms of gastrointestinal prolapse.^{5,23} It should be noted that benign misplaced epithelium, with or without associated acellular mucin pools, may rarely extend beyond the submucosa to involve deeper wall structures, including the muscularis propria and even into the pericolonic adipose tissue.

The subsequent steps after determining that there is true submucosal invasion are discussed in detail below. Briefly, the pathologist also evaluates the depth of the invasion within the polypectomy specimen. A histologic grade is assigned and the lesion is scrutinized for evidence of lymphatic or blood vessel invasion. The completeness of resection is then evaluated by noting the status of the margin and finally, an estimate of the risk of metastasis can be provided through synthesis of these composite microstaging data (see below).

Determine Depth of Invasion

Nodal metastasis from a carcinoma in which the invasion extends into the submucosa of the head of a pedunculated polyp or at any level into the stalk is *extremely* rare, certainly less than 1%.^{9,24} The probability of nodal metastasis becomes significant only with invasion into the submucosa of the bowel wall proper (Table 4), as occurs in sessile lesions or in pedunculated lesions with invasion beyond the stalk.^{9,24} The data shown in Table 4 suggest that the overall risk of nodal metastasis is approximately 5% when invasion is limited to the submucosa of the bowel wall itself (i.e., the average of 11%, 0% and 6.5%) and the lesion has been completely excised.^{8,13,15}

TABLE 4: DEPTH OF INVASION AND PREVALENCE OF POSITIVE LYMPH NODES

<i>Author No.</i>	Morson ¹⁵ (2084)	Minsky ¹³ (168)	Grigg ⁸ (268)
<i>Depth of Invasion</i>	<i>% Positive Lymph Nodes</i>		
Submucosa	11	0	6.5
M. propria	12	28	---
Through m.p.	58	39	---

All rectal cancers; all resected by LAR or APR

Determine Histologic Grade & Angiolymphatic Invasion

High-grade or poorly differentiated tumors are more likely to have lymph node metastases than well or moderately differentiated lesions.^{2,7,24} The exact percentage with nodal metastases is difficult to determine because of the small numbers of endoscopically

resectable cases that are poorly differentiated and because of frequent confounding factors such as synchronous angiolymphatic invasion or invasion into the submucosa of the bowel wall. If invasion of vessels or lymphatic channels is present, there is also a higher probability of positive nodes,¹⁴ but likewise the confounding presence of a poorly-differentiated tumor makes this difficult to assess independently.^{2,9,14,24} Nonetheless, based on limited data in endoscopic polypectomy specimens, both factors appear to increase the risk of nodal metastasis and are indicators for colectomy in the absence of mitigating clinical circumstances. The degree to which they increase the risk remains unknown due to limited case numbers.

Endoscopic Completeness of Resection

The status of the polypectomy margin, as an index of prognosis, is controversial. Morson found that if the polypectomy margin was free of the tumor, *regardless of the distance from the neoplasm to the electrocautery margin, the prognosis was uniformly favorable. When the carcinoma extended to the electrocautery margin, but when the endoscopist thought that the lesion was completely resected, the prognosis was again favorable.*¹⁶ This probably reflects the destruction of an additional zone of 0.2-0.3 cm of tissue by electrocautery within the patient beyond what is resected and processed by the pathologist. In contrast, when the endoscopist thought that the excision was incomplete or questionable, the prognosis was less favorable.¹⁶

In addition to the extension of the margin by cautery tissue destruction, the endoscopist also sees the lesion in 3-dimensions, both before and after polypectomy, so that the endoscopist knows if gross lesion remains behind. Furthermore, this information is virtually never disclosed to the pathologist! Thus, the pathologist may state that a lesion is resected based on the histologic appearance of the sample received, when in fact the sample was only a small portion of the lesion and the endoscopist is fully aware that a larger lesion remains in the patient. In marked contrast to the endoscopist's macroscopic 3-dimensional view, the pathologist sees only a tiny fraction of the lesion's margin, and essentially in only 2-dimensions via relatively few 5 µm thick microscopic slices through the margin which in reality is many millimeters or even centimeters in thickness. Thus, based on the enormous sampling limitations of the histologic view, it can virtually *never* be stated with histologic certainty that the lesion has been completely resected. It is the endoscopist's opinion on this matter that should determine this favorable or unfavorable status of the margin, not the pathologist's.

Unfortunately, few studies of endoscopically resected adenomas with adenocarcinomas even comment on the *endoscopist's* assessment of the completeness of excision. Instead, some have suggested that histologic extension of the carcinoma to within 0.1 or 0.2 cm or less of the margin is an unfavorable prognostic sign.^{2,24} Utilization of this criterion as an indication for colectomy of course produces a favorable outcome because the probability of nodal metastasis is distinctly low in this subset of individuals. As has already been discussed, the risk of nodal metastasis is only <1% to ~5% for these lesions without angiolymphatic invasion or poor differentiation (see above). If one uses extension of the tumor to within 0.2 cm or less of the margin (or actually to within any arbitrary distance) as a criterion for resection, one increases the resection rate to an unacceptably high level,

in the opinion of this author. Thus, careful communication with the endoscopist concerning the status of the margin is mandatory in planning the optimal management for a patient with carcinoma arising in an adenoma. If the endoscopist thinks the lesion is completely resected, this is almost always the case. If there is any concern that an endoscopically respectable lesion may not have been completely resected, then additional endoscopic resection or biopsies at the site and/or endoscopic ultrasound may prove helpful.

As a practical matter, this author never provides measurements concerning the resection margin in an endoscopically resected adenoma with adenocarcinoma, but rather only provides one of two comments on this issue: either that the lesion *appears completely resected*, or that the *completeness of resection cannot be assessed histologically*. The latter commentary is used if carcinoma is either at the cauterized resection margin, or for polyps resected in a piecemeal fashion such that the true margin cannot be known histologically. *In either case, a statement is also provided that the endoscopist's opinion on the completeness of resection is more important than the pathologist's.*

SUMMARY OF FACTORS THAT APPEAR TO INCREASE THE PROBABILITY OF NODAL METASTASES

Unless there is invasion into the submucosa of the underlying bowel wall, incomplete excision, poor differentiation or angiolymphatic invasion, surgery is not indicated because of the low risk of nodal metastasis (<1%) that could potentially be cured by a resection.^{9-11,24,27} Authorities are in uniform agreement that pedunculated lesions of this type are adequately treated by endoscopic resection alone.

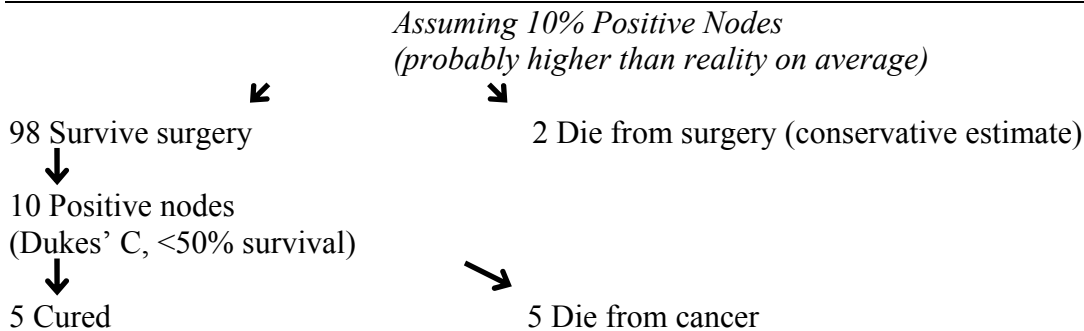
In fact, the risk of nodal metastasis is low enough (~5%), that even with invasion into the submucosa of the underlying bowel wall (in sessile lesions mostly), an argument can also be made for not pursuing surgical resection if the tumor has been completely removed endoscopically (see Tables 5 and 6). Thus, the risk of nodal metastasis must be weighed against the risk of operative morbidity and mortality from a segmental colectomy with nodal dissection. The mortality risk is not unappreciable and averages between 2% to almost 7%.^{3,21,25} The mortality risk of colorectal cancer surgery rises significantly with increasing patient age, as determined from the Nationwide Inpatient Sample for all patients undergoing colorectal cancer surgery during 1997 (N=20,862).³ In this database, age-stratified mortality was: age <50, 0.8%; age 50-65, 1.3%; age 66-80, 2.9%, and age >80, 6.9%.³ Surgical mortality is also greater with low-volume surgical centers or surgeons relative to high-volume centers or surgeons.^{3,21}

The final factor to be considered in the overall risk assessment and management plan, in addition to microstaging data and operative mortality, is that patients who are discovered to have positive lymph nodes, namely those with Dukes' C adenocarcinoma, have a cure rate of 50% or less even with surgery (see Tables 5 and 6).

If surgery is pursued for a completely endoscopically resected adenocarcinoma that is well to moderately differentiated and without angiolymphatic invasion, then all parties

must be aware of the high probability (95-99%) that nothing will be found in the resection specimen.

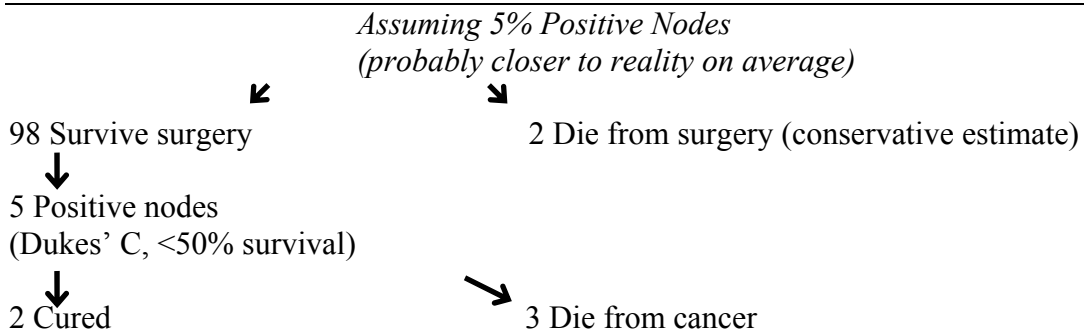
**TABLE 5: SESSILE CARCINOMA WITH SUBMUCOSAL WALL INVASION
100 PATIENTS -- SURGICAL RESECTION**



THUS

100 operations, 5 patients cured
7 Dead - 2 from surgery, 5 from cancer
10 would have died if no operations done

**TABLE 6: SESSILE CARCINOMA WITH SUBMUCOSAL WALL INVASION
100 PATIENTS-- SURGICAL RESECTION**



THUS

100 operations, 2 patients cured
5 Dead - 2 from surgery, 3 from cancer
5 would have died if no operations done

REFERENCES - CARCINOMA IN ADENOMA

1. Atkin WS, Morson BC, Cuzick J. Long-term risk of colorectal cancer after excision of rectosigmoid adenomas. *N Engl J Med* 1992;326:658-662.
2. Cooper HS, Deppisch LM, Gourley WK, et al. Endoscopically removed malignant colorectal polyps: clinicopathologic correlations. *Gastroenterology*

- 1995;108:1657-1665.
3. Dimick JB, Cowan JA, Upchurch GR, et al. Hospital volume and surgical outcomes for elderly patients with colorectal cancer in the United States. *J Surg Res* 2003;114:50-56.
 4. Fenoglio CM, Kaye GI, Lane N. Distribution of human colonic lymphatics in normal, hyperplastic, and adenomatous tissue: its relationship to metastasis from small carcinomas in pedunculated adenomas, with two case reports. *Gastroenterology* 1973;64:51-66.
 5. Gardiner GW, McAuliffe N, Murray D. Colitis cystica profunda occurring in a radiation-induced colonic stricture. *Hum Pathol* 1984;15:295-298.
 6. Gillespie PE, Chambers TJ, Chan KW, et al. Colonic adenomas - a colonoscopic survey. *Gut* 1979;20:240-245.
 7. Greene FL. Epithelial misplacement in adenomatous polyps of the colon and rectum. *Cancer* 1974;33:206-217.
 8. Grigg M, McDermott FT, Pihl EA, et al. Curative local excision in the treatment of carcinoma of the rectum. *Dis Colon Rectum* 1984;27:81-83.
 9. Haggitt RC, Glotzbach RE, Soffer EE, et al. Prognostic factors in colorectal carcinoma arising in adenomas: implications for lesions removed by endoscopic polypectomy. *Gastroenterology* 1985;89:328-336.
 10. Jass JR. Malignant colorectal polyps. *Gastroenterology* 1995;109:2034-2035.
 11. Kyter S, Begin LR, Gordon PH, et al. The care of patients with colorectal polyps that contain invasive adenocarcinoma: endoscopic polypectomy or colectomy? *Cancer* 1992;70:2044-2050.
 12. Lotfi AM, Spencer RJ, Ilstrup DM, et al. Colorectal polyps and the risk of subsequent carcinoma. *Mayo Clin Proc* 1986;61:337-343.
 13. Minsky BD, Rich T, Recht A, et al. Selection criteria for local excision with or without adjuvant radiation therapy for rectal cancer. *Cancer* 1989;63:1421-1429.
 14. Minsky B, Mies C. The clinical significance of vascular invasion in colorectal cancer. *Dis Colon Rectum* 1989;32:794-803.
 15. Morson BC. Factors influencing the prognosis of early cancer of the rectum. *Proc Roy Soc Med* 1986;59:607-608.
 16. Morson BC, Whiteway JE, Jones EA, et al. Histopathology and prognosis of malignant colorectal polyps treated by endoscopic polypectomy. *Gut* 1984;25:437-444.
 17. Muto T, Bussey HJR, Morson BC. Pseudocarcinomatous invasion in adenomatous polyps of the colon and rectum. *J Clin Pathol* 1973;26:25-31.
 18. Muto T, Bussey HJ, Morson BC. The evolution of cancer of the colon and rectum. *Cancer* 1975;36:2251-2270.
 19. Neugut AI, Johnsen CM, Forde KA, et al. Recurrence rates for colorectal polyps. *Cancer* 1985;55:1586-1589.
 20. Rickert RR, Auerbach O, Garfinkel L, et al. Adenomatous lesions of the large bowel: an autopsy survey. *Cancer* 1979;43:1847-1857.
 21. Schrag D, Panageas KS, Riedel E, et al. Surgeon volume compared to hospital volume as a predictor of outcome following colon cancer resection. *J Surg Oncol* 2003;83:68-78.
 22. Shinya H, Wolff WI. Morphology, anatomic distribution and cancer potential of

- colonic polyps. *Ann Surg* 1979;190:679-683.
23. Sobin LH. Pseudoinvasive intestinal polyps. *Dig Dis Pathol* 1989;2:1-12.
 24. Volk EE, Goldblum JR, Petras RE, et al. Management and outcome of patients with invasive carcinoma arising in colorectal polyps. *Gastroenterology* 1995;109:1801-1807.
 25. Welch CE, Malt RA. Abdominal surgery. *N Engl J Med* 1979;300:705-712.
 26. Williams CB, Macrae FA. The St. Marks' neoplastic polyp follow-up study. *Front Gastrointest Res* 1986;10:226-242.
 27. Williams CB, Saunders BP, Talbot IC. Endoscopic management of polypoid early colon cancer. *World J Surg* 2000;24:1047-1051.
 28. Winawer SJ, Zauber AG, O'Brien MJ, et al. Randomized comparison of surveillance intervals after colonoscopic removal of newly diagnosed adenomatous polyps. *N Engl J Med* 1993;328:901-906.

Polyps with no Names or with Obscure Names

Henry D. Appelman, MD
University of Michigan

Polyps with no names or with obscure names

Henry D. Appelman, M.D.
University of Michigan
appelman@umich.edu

We only recognize a few types of polyps,
and since we often forget that there are
others that have yet to be named,
we try to fit every polyp into a category
with a name that we know.

What we want to know about a polyp

1. Is there too much artifact for me to see the damned thing?
2. Is it neoplastic?
3. Is it part of a syndrome?
4. Does it indicate a cancer risk?
5. If none of these, does it still have a name?
6. If it doesn't, what shall I call it?

A fair number of polyps in the colon get
called "juvenile polyps" that aren't.

Why?

Because they are round and have dilated
crypts, and because juvenile polyps are not
well defined.

What polyps have names?

They differ somewhat by site

All sites

adenomas

juvenile

Stomach

fundic gland

hyperplastic: nothing like the colonic polyp

P-J hamartomas

Colorectum

hyperplastic: nothing like the gastric polyp

new names for mainly prolapsed mucosa

A fair number of bumps get called
"hamartomas"

Why?

Because they are made up of normal or near
normal epithelial structures
and because the word "hamartoma" is a good
place to hide, if you don't have another name
in mind.

Some polyps are lumps containing prolapse changes including smooth muscle fibers extending from the muscularis mucosae into the mucosal base villiform surface, with occasional necrotic tips, distortion of tubular architecture, reactive changes in surface and superficial tubular epithelium

Some of these now have names

Maybe 5-10% of endoscopic polyps contain histologically normal mucosa

If we serial section them or turn the block around and start cutting from the back side, some of them will turn out to be something like a minute adenoma or hyperplastic polyp

Does such a tiny adenoma have any clinical meaning, other than it forces the patient into an expensive and unpleasant follow-up program?

Is it worth the effort?

Formerly nameless polyps that now have names

- Diverticulosis associated polypoid prolapsed mucosa (Kelly polyp)
- Inflammatory myoglandular polyp (never caught on here)
- Cap polyp (more prolapsed mucosa)
- Transitional mucosal polyp (the edge of something)
- The new fibroblastic polyp

Not all GI polyps are easy to classify

some are hybrids
some don't fit
some are pimples
some have obscure literature

They are annoying!

They will make you crazy!

They make me crazy!

The more we keep up with the literature, the more names we know, since new names come out from time to time.

This is the same situation with everything else, like inflammations or carcinomas

The zit analogy:

A zit is like a polyp, but it is on the skin

Zits occur in almost everyone

They frequently are biopsied

Dermatologists and dermatopathologists have already given names to 3500 zits based on location
color
contours
texture (how they feel when you rub them)

The GI tract has more surface area than the skin
 Zits occur in the gut mucosa.
 Possibly they are as common as they are on the skin.

Gastroenterologists and GI pathologists have only named 532 zits based on GOKW.

We have 2968 zits still to name to match the skin people

Polyps with no names are found more often in the colon than in the stomach. Why?

- More colonoscopic exams than upper endoscopic exams
- more surface area in the colon than in the stomach
- gastric mucosa is commonly slightly nodular anyway (area gastricae)

Unnamed polyps are common!

We try to fit them into categories in which they do not belong.

So, they take up a lot of our time

When will we learn?

Polyps with no name

Simplified, probably useless classification

1. Polyps due to excess epithelium
2. Polyps due to excess lamina propria
3. Polyps due to stroma that is not lamina propria
4. Polyps that are mixed
5. Polyps that are none of the above

Situations in which unnamed polyps occur

The polyp does not correspond to anything I know or that has a picture in a book or journal

The polyp kind of looks like something I know, or maybe several somethings, but not enough like any of them

Polyps due to excess lamina propria

These are likely to be called "inflammatory pseudopolyps"

This might be an appropriate name, since they tend to look like the IPPs that occur in ulcerative colitis.

However, the IPP designation might be dangerous. Some clinicians seem to equate IPPs with UC. An IPP diagnosis might lead to an assumption that the patient has UC

Gastric unnamed polyps

The stomach has 2 common polyps
 fundic gland polyps: clear cut anatomy
 hyperplastic polyps: confused anatomy

Therefore, we probably throw more things into the hyperplastic category than it deserves because we do not know the limits of hyperplastic polyps in the stomach.

Why is it important to give every polyp a name?

The clinicians want it.

Or do they?

If is not an adenoma, do they really care what name we give to it?

Only adenomas lead to clinical decisions

An unnamed gastric polyp

The distal polyp that looks like it has too much mucosa, maybe with a little prolapse change at the base.

Why is it important to give every polyp a name?

We pathologists want it

This is probably closer to the truth

Sometimes the specific name is less important than the satisfaction of finding (concocting, etc) a name

And believing that we made (up) the right choice

The house officer polyp rules:

If you can't name a polyp in 20 seconds then it probably does not have a name or the reference to it is so obscure that you do not know it exists, or you have had poor training.

If you think you can name it after 20 and before 30 seconds, then you better be sure that you are not putting it in the wrong place.

If you still can't name it by 30 seconds, make up a name: "Benign mucosal polyp" is acceptable

References: It is almost impossible to find references to things that have no names. If they had names, then they would have references, and they would not be the subject of this discussion. Anyway, here are some references to a few things that got names recently:

1. Whitelaw SC, Murday VA, Tomlinson IPM, et al. Clinical and molecular features of the hereditary mixed polyposis syndrome. *Gastroenterol.* 112:327-334, 1997. This describes a family that makes mixed juvenile-adenomatous-hyperplastic polyps-----or something!
2. Kelly JK. Polypoid prolapsing mucosal folds in diverticular disease. *Am J Surg Pathol.* 15:871-878, 1991
3. Nakamura S-I, Kino I, Akagi T. Inflammatory myoglandular polyps of the colon and rectum. A clinicopathological study of 32 pedunculated polyps distinct from other types of polyps. *Am J Surg Pathol.* 16:772-779, 1992 (these look like juvenile polyps with smooth muscle in the center, and they occur in adults.)
4. Burke AP, Sobin LH: Eroded polypoid hyperplasia of the rectosigmoid. *Am J Gastroenterol.* 85:975-980, 1990
5. Tendler DA, Aboudola S, Zacks JF, et al: Prolapsing mucosal polyps: an underrecognized for of colonic polyp---a clinicopathological study of 15 cases. *Am J Gastroetnerol.* 97:370-376, 2002
6. Chetty R, Bhathal PS, Slavin JL: Prolapse-induced inflammatory polyps of the colorectum and anal transitional zone. *Histopathol.* 23:63-67, 1993
7. Campbell AP, Cobb CA, Chapman RWG, et al: Cap polyposis—an unusual cause of diarrhea.. *Gut.* 34:562-564, 1993
8. Franzin G Scarpa A Dina R Zamboni G Frattoni A. Transitional polyps of the colon. *Endoscopy* 14(5):174-5, 1982
9. Heilmann KL, Schmidbauer G, Schyma G. The transitional polyp of the colorectal mucosa. *Path Res Pract.* 182:690-693, 1987

Serrated Colorectal Polyps: New Challenges to Old Dogma

Kenneth P. Batts, M.D.
Abbott Northwestern Hospital
Minneapolis, MN

Introduction

Overview of Known Colorectal Cancer Pathways Traditionally, the two main categories of colorectal epithelial polyps have been adenomatous and hyperplastic polyps (HPPs). It has long been recognized that adenomatous polyps are premalignant lesions, and indeed the discovery of the molecular basis of the now famous adenoma-carcinoma sequence is one of the scientific triumphs of the past quarter century³⁹. This pathway is most often seen in sporadic colorectal cancers but also characterizes familial adenomatous polyposis and is thus called the “adenomatous polyposis coli” or “APC” pathway. Subsequently, another molecular pathway to colorectal cancer, the DNA mismatch repair pathway, has also been described.¹ Like the APC pathway, this can be seen in either sporadic colorectal adenocarcinomas or an inherited condition called “hereditary non-polyposis colon cancer” (HNPCC). The key elements of this pathway are dysfunctional mismatch repair enzymes³⁵ and subsequent accumulation of mutations, some of which may involve key oncogenes.

“Hyperplastic Polyps” and Cancer

Morphologic Evidence Linking “Hyperplastic Polyps” and Cancer Initially regarded as benign and metaplastic, there is now considerable and compelling evidence implicating at least a subset of what have traditionally been called HPPs in the development of a subset of colorectal carcinomas and a number of colorfully titled commentaries and editorials supporting this have been spawned.^{12,18,20,42} Morphologic evidence for this has come from a variety of directions. There have been scattered reports and small series of adenocarcinomas being associated with “giant” or “large” hyperplastic polyps (usually defined as > 1 cm).^{2,41} Presence of multiple “HPPs” in the form of hyperplastic polyposis²⁹ (also known as “giant” hyperplastic polyposis²⁴ or “serrated adenomatous polyposis”),³⁷ is clearly associated with the development of adenocarcinoma. Short of overt hyperplastic polyposis, polyps traditionally called hyperplastic polyps seem to be a fertile soil for a subset of colorectal cancers given the observation that in patients with microsatellite unstable (MSI) colorectal cancers there is an increase in serrated polyps (HPPs and serrated adenomas) but not in adenomas in the background mucosa.¹⁴ A large series of more than 90 MSI colorectal cancers in which HPPs had been had been diagnosed near the site of the colorectal cancer at earlier examination further implicates HPPs in a subset of colorectal carcinoma.¹⁰ Serrated polyps have been noted adjacent to 5.8% of colorectal cancers in one study.²⁷

Molecular Evidence for the “Serrated Pathway” of Colorectal Cancer Triggered by the morphologic observations, molecular studies now provide convincing evidence for a pathway from HPPs (or HPP-like polyps) to colorectal carcinoma. This is being

described as the “serrated” pathway to colorectal cancer.^{13,23} Our understanding of this pathway is still evolving and details are discussed in a number of recent articles.^{7,8,13,19,21,22,28,38,40} Early steps appear to involve decreased cell death (apoptosis) in serrated polyps leading to prolonged cell life, an increased concentration of epithelial cells resulting in a serrated appearance,³⁴ and a presumed susceptibility to DNA methylation. Foci rich in cytosine-guanine bases are particularly susceptible to methylation (CpG island methylator phenotype or CIMP for short). This may result in methylation-induced transcriptional silencing of the promoters for tumor suppressor genes. Hypermethylation is observed in 20-40% of colon cancers, and in about one third of these hypermethylation induced inactivation of the DNA mismatch repair gene hMLH1 has occurred with resulting accumulation of DNA microsatellite repeat sequences of DNA of either low (MSI-L) or high (MSI-H) degrees (ie “microsatellite instability”).³⁸ Of interest, among the mutated genes there is evidence that the serrated pathway involving SAs is associated with BRAF mutations whereas the pathway through MHAPs may involve Kras mutations.⁸

Implications for the Diagnostic Surgical Pathologist While the concept of a “serrated pathway” to colorectal neoplasia is very exciting from a scientific sense, from a practical perspective it raises many as-yet unanswered issues. The challenges in this area may not be readily apparent when reading literature on this topic and fall into the categories of terminology, morphologic reproducibility, conceptual framework, and treatment levels.

Terminology Challenges

Early History of the “Serrated Adenoma” The common morphologic thread in the “serrated pathway” is the name giving feature of epithelial serrations. Traditionally, serrated epithelial neoplasms without dysplasia were termed HPPs, but the term “serrated adenoma” (SA) was applied in 1990 to a subset of polyps that had admixed features of a serrated HPP-like architecture but also dysplasia.²⁶ Thus, in most practices, through the 1990’s serrated polyps were classified as either HPPs, SA’s, or mixed HPP/adenomas (MHAPs), the latter being polyps with admixed HPP and adenomatous areas. In most practices, SA’s have been rare, reflecting the incidence of <1% noted in the original SA article²⁶ and in other large series.^{3,17} Furthermore, for management purposes, SA’s have been largely regarded as equivalent to adenomas, as reflected in major textbooks.⁹ We suspect that in many daily practices, SAs may have been underestimated and many called villous adenomas since the absence of a known significance for the serrated morphology would lead one to perhaps not spend too much time worrying about whether a dysplastic polyp demonstrated serrations or not

The Birth of the “Sessile Serrated Adenoma” (aka “Sessile Serrated Polyp”) There is a movement to potentially expand the category of “SA”, largely by including a subset of what have usually been called “HPPs”. Torlakovic and Snover recognized in 1996 that the “HPPs” in HPPosis were morphologically different from traditional HPPs and proposed the term “serrated adenomatous polyposis” for this syndrome.³⁷ Their morphologic criteria are summarized in Table 1, major components being a tendency for an atypical architecture (sessile growth, dilated and often laterally branching crypts, and

sometimes exaggerated serrations) and abnormal maturation (rounded hyperchromatic nuclei with nucleoli and mitotic figures extending into mid and upper crypts). These polyps are not confined to HPPosis, however. Goldstein et al noted that all of the “HPP-like” polyps antedating MSI-H cancers have the same morphologic characteristics as the polyps in HPPosis¹⁰ and my personal experiences support this.⁴ I suspect many of the “giant” HPPs in the literature and perhaps many of the “HPPs” with unusual molecular characteristics may also fit into this category. These polyps have a tendency to be right sided, large, sessile, and endoscopically poorly circumscribed, sometimes mimicking enlarged folds.

The term “serrated adenomatous polyposis” was initially largely ignored, probably due to the fact that most of these polyps did not appear to have the obvious sharply demarcated surface dysplasia that comfortably identifies adenomatous polyps of the colon. In fact this apparent expanding of the SA category was probably justifiable as the original SA article by Longacre contains polyps that do fit the description by Torlakovic and about one third of the original Longacre SA series had originally been called HPPs, implying that the “dysplasia” may not have been obvious.

I believe the polyp described by Torlakovic is real, but it is very difficult to decipher the literature on this polyp since it hides under a plethora of names: HPPs, “giant” or “large” HPPs, SA’s, sessile SA’s,³⁶ HPP-like polyps,¹⁰ inverted HPPs,^{32,33} “colorectal polyps with epithelial serrated proliferation”¹¹, sessile serrated polyps,^{4,19} and likely still others. It is patently clear that this polyp needs a single name in order to better identify and study it as a discrete entity and to devise treatment guidelines. The term currently used in the Twin Cities is “sessile SA”, taken from the work of local investigators Emina Torlakovic and Dale Snover^{36,37} and endorsed by Goldstein.¹⁰ I believe “SSA” is a reasonable name and use it in my daily practice because of local precedence. I will admit, however, that my personal preference is the name “sessile serrated polyp” (SSP)^{4,19} because it: a) reflects that these lesions lack the traditional-type dysplasia that we see in other “adenomas” of the colon, and b) the word “adenoma” may prompt clinicians into doing segmental resection for endoscopically unresectable polyps when we don’t know at the current time whether this is always appropriate. Regardless of the term you use, it is important that your constituent clinicians understand the biologic nature of the polyp you are diagnosing. Only time will determine what term is ultimately favored by the medical community at large.

Reproducibility Issues

The trust placed in a pathologist’s diagnosis will be diminished if it becomes apparent that a given lesion cannot be reliably placed into the same diagnostic category by the pathology community. This is of considerable relevance to this issue since hyperplastic polyps are so common and both Torlakovic³⁶ and Goldstein¹⁰ noted that while SSPs (their “SSAs”) tend to be larger than HPPs and are more often right sided, about 15-20% of smaller, left-sided “HPPs” have the morphologic features of SSPs. These are almost surely nearly always regarded as HPPs in daily practice today.

It is not too difficult to identify large SSAs, but I have less confidence in my ability to diagnose the potential 15-20% of smaller serrated polyps that may be SSAs. Lack of data on reproducibility makes the transfer of the concept of SSA to clinical practice fraught with uncertainty, particularly since in the pre-SSA era one study of community-based pathologists showed that HPPs were recognized accurately only 75% of the time.³⁰

Conceptual Issues – Understanding the Disease Process

What Lesions Participate in the Serrated Pathway? The relationship between the components of the serrated polyp family [HPPs, “SSPs”, MHAPs and SAs] is not entirely clear but some fairly strong inferences can be made at this time:

1) Molecular and immunohistochemical data fairly convincingly places traditional SAs in the serrated family of polyps (with HPP and SSP) rather than the traditional adenoma family. Similar to HPPs and unlike adenomas, SAs tend to demonstrate a gastric-type mucin profile.^{5,25,43} Furthermore, a mouse model exists for a serrated adenoma/mixed polyp pathway¹⁵ and in humans a propensity for microsatellite instability links SAs more closely with HPPs than traditional adenomas.¹⁶

2) The majority of mixed polyps with serrated and traditional adenoma-like components (MHAPs) seem to be examples of serrated polyps developing dysplasia as a precursor to malignancy based on molecular data^{8,16,28} and anecdotal experience.

3) The SSP → either SA or MHAP → carcinoma sequence seems likely, however it is not entirely clear whether the HPP is the precursor to the SSP (as seems to be most commonly assumed by most authors) or whether HPPs and SSPs are morphologically similar cousins.³⁶ Obviously addressing this issue is complicated by the frequent difficulties in reliably distinguishing HPPs from SSPs and the difficulty in interpreting existing literature due to mixed terminologies and definitions. The answer is not currently known.

4) There is emerging evidence that the carcinomas arising from the serrated pathway have some characteristic morphologic features - serrated architecture, eosinophilic epithelium and abundant mucus.²⁷ These features probably serve as markers for tumors arising via the serrated pathway. The term “serrated adenocarcinoma” is being used to describe these tumors.^{13,44}

Can we call the atypia in SSAs “dysplasia”? Classical teaching regarding adenomas of the colon requires the presence of at least surface dysplasia with variable extension into crypts and a sharp demarcation from adjacent non-dysplastic epithelium. In contrast, many of the lesions being called “SAs” in the literature (the SSA in our parlance) appear to demonstrate only a bottom-up form of atypia²² that some regard as an alternative, early form of dysplasia.³¹ While this may well turn out to be the case, the bottom-up rather than top-down appearance and the typical lack of a sharp clonal-type demarcation for the atypia in these lesions helps make this putative form of dysplasia very difficult to identify with certainty in daily practice. Whether or not this should process should be equated

with adenomatous-type dysplasia remains unclear and I prefer not to refer to the bottom-up abnormal maturation as overt “dysplasia” at present – perhaps this process needs its own name.

Treatment Issues – Taking these Concepts from Bench to Bedside

The key practical, translational issue is how to manage patients with the various serrated polyps, the main clinical decisions being what to do with incompletely excised polyps, whether to do pan-colonoscopy when index lesions are identified on proctoscopy or sigmoidoscopy, and whether long-term endoscopic surveillance is needed (and if so, the frequency of such). Currently, straightforward guidelines exist for the management of adenomatous polyps⁶ but guidelines for the serrated family of polyps are lacking and sorely needed.

Summary

There is no doubt about the existence of a serrated pathway of colorectal cancer, but there is little information to date about how to transfer this information to clinical practice. There is considerable evidence that a largely unrecognized HPP-like polyp with subtle morphologic features that distinguish it from usual HPPs is an important early step in the serrated pathway – this polyp is termed “sessile serrated adenoma” locally. This polyp tends to often be large, sessile, and right sided and can progress to cancer by way of either transition to overt dysplasia (MHAP) or “traditional” serrated adenoma. Data are still lacking on the natural history of these lesions and there are no published guidelines for the optimal treatment of these lesions.

References

- 1) Aaltonen LA, Peltomaki P, Leach FS, et al. Clues to the pathogenesis of familial colorectal cancer. *Science*. 1993 May 7;260(5109):812-6.
- 2) Azimuddin K, Stasik JJ, Khubchandani IT, et al. Hyperplastic polyps: "more than meets the eye"? Report of sixteen cases. *Dis Colon Rectum*. 2000 Sep;43(9):1309-13.
- 3) Bariol, Hawkins NJ, Turner JJ, et al. Histopathological and clinical evaluation of serrated adenomas of the colon and rectum. *Mod Pathol*. 2003 May;16(5):417-23.
- 4) Batts KP, Burgart LJ, Goldblum JR, et al. Sessile Serrated Polyp: A Multi-Institutional Incidence Study (abstract). *Modern Pathology* 2002; 15(1):113A.
- 5) Biemer-Huttmann A-E, Walsh MD, McGuckin MA, et al. Immunohistochemical staining patterns of MUC1, MUC2, MUC4, and MUC5AC mucins in hyperplastic polyps, serrated adenomas, and traditional adenomas of the colorectum. *J Histochem Cytochem*. 1999 Aug;47(8):1039-48
- 6) Bond JH. Polyp guideline: diagnosis, treatment, and surveillance for patients with colorectal polyps. Practice Parameters Committee of the American College of Gastroenterology. *Am J Gastroenterol*. 2000 Nov;95(11):3053-63.
- 7) Chan AO, Issa JP, Morris JS, et al. Concordant CpG island methylation in hyperplastic polyposis. *Am J Pathol*. 2002 Feb;160(2):529-36.

- 8) Chan TL, Zhao W, Leung SY, et al. BRAF and KRAS mutations in colorectal hyperplastic polyps and serrated adenomas. *Cancer Res.* 2003 Aug 15;63(16):4878-81.
- 9) Fenoglio-Preiser CF. *Gastrointestinal Pathology – An Atlas and Text*, 2nd edition. Fenoglio-Preiser CF, Noffsinger AE, Stemmerman GN, Lantz PE, Listrom MB, Rilke FO, eds., Lippincott-Raven, 1998.
- 10) Goldstein NS, Bhanot P, Odish E, et al. Hyperplastic-like colon polyps that preceded microsatellite-unstable adenocarcinomas. *Am J Clin Pathol.* 2003 Jun;119(6):778-96.
- 11) Hamatani S, Wada R, Tsujimoto S, et al. Histomorphometric characteristics and cellular kinetics of colorectal polyps with epithelial serrated proliferation adjacent to carcinoma. *Oncol Rep.* 2001 Jan-Feb;8(1):49-55.
- 12) Hamilton SR. Origin of colorectal cancers in hyperplastic polyps and serrated adenomas: another truism bites the dust. *J Natl Cancer Inst.* 2001 Sep 5;93(17):1282-3.
- 13) Hawkins NJ, Bariol C, Ward RL. The serrated neoplasia pathway. *Pathology.* 2002 Dec;34(6):548-55.
- 14) Hawkins NJ, Ward RL. Sporadic colorectal cancers with microsatellite instability and their possible origin in hyperplastic polyps and serrated adenomas. *J Natl Cancer Inst.* 2001 Sep 5;93(17):1307-13.
- 15) Hohenstein P, Molenaar L, Elsinga J, et al. Serrated adenomas and mixed polyposis caused by a splice acceptor deletion in the mouse *Smad4* gene. *Genes Chromosomes Cancer.* 2003 Mar;36(3):273-82.
- 16) Iino H, Jass JR, Simms LA, et al. DNA microsatellite instability in hyperplastic polyps, serrated adenomas, and mixed polyps: a mild mutator pathway for colorectal cancer? *J Clin Pathol.* 1999 Jan;52(1):5-9.
- 17) Iwabuchi M, Sasano H, Hiwatashi N, et al. Serrated Adenoma: A Clinicopathological, DNA Ploidy, and Immunohistochemical Study. *Anticancer Research* 2000;20:1141-1148, 2000
- 18) Jass JR. Hyperplastic polyps of the colorectum – innocent or guilty? *Dis Colon Rectum* 2001;44(2):163-166.
- 19) Jass JR. Hyperplastic-like polyps as precursors of microsatellite-unstable colorectal cancer. *Am J Clin Pathol.* 2003 Jun;119(6):773-5.
- 20) Jass JR. Serrated adenoma of the colorectum. A lesion with teeth. *Am J Pathol* 2003;162(3):705-708.
- 21) Jass JR, Iino H, Ruzskiewicz A, et al. Neoplastic progression occurs through mutator pathways in hyperplastic polyposis of the colorectum. *Gut.* 2000 Jul;47(1):43-9.
- 22) Jass JR, Whitehall VL, Young J, et al. Emerging concepts in colorectal neoplasia. *Gastroenterology.* 2002 Sep;123(3):862-76.
- 23) Jass JR. Serrated route to colorectal cancer: back street or super highway? *J Pathol.* 2001 Mar;193(3):283-5.
- 24) Jeevaratnam P, Cottier DS, Browett PJ, et al. Familial giant hyperplastic polyposis predisposing to colorectal cancer: a new hereditary bowel cancer syndrome. *J Pathol.* 1996 May;179(1):20-5.

- 25) Koike M, Inada K, Nakanishi H, et al. Cellular differentiation status of epithelial polyps of the colorectum: the gastric foveolar cell-type in hyperplastic polyps. *Histopathology*. 2003 Apr;42(4):357-64.
- 26) Longacre TA, Fenoglio-Preiser CF. Mixed hyperplastic adenomatous polyps/serrated adenomas. A distinct form of colorectal neoplasia. *Am J Surg Pathol*. 1990 Jun;14(6):524-37.
- 27) Makinen MJ, George SMC, Jenvall P, et al. Colorectal carcinoma associated with serrated adenoma--prevalence, histological features, and prognosis. *J Pathol*. 2001 Mar;193(3):286-94.
- 28) Park SJ, Rashid A, Lee JH, et al. Frequent CpG island methylation in serrated adenomas of the colorectum. *Am J Pathol*. 2003 Mar;162(3):815-22.
- 29) Renaut AJ, Douglas PR, Newstead GL. Hyperplastic polyposis of the colon and rectum. *Colorectal Dis*. 2002 May;4(3):213-215.
- 30) Rex DK, Alikhan M, Cummings O, Ulbright TM. Accuracy of pathologic interpretation of colorectal polyps by general pathologists in community practice. *Gastrointest Endosc*. 1999 Oct;50(4):468-74.
- 31) Rubio CA. Colorectal Adenomas: Time for Reappraisal. *Pathology Res Pract* 2002;198:615-620.
- 32) Shepherd NA. Inverted hyperplastic polyposis of the colon. *J Clin Pathol*. 1993 Jan;46(1):56-60.
- 33) Sobin LH. Inverted hyperplastic polyps of the colon. *Am J Surg Pathol*. 1985 Apr;9(4):265-72.
- 34) Tateyama H, Wenxin L, Takahashi E, et al. Apoptosis index and apoptosis-related antigen expression in serrated adenoma of the colorectum: the saw-toothed structure may be related to inhibition of apoptosis. *Am J Surg Pathol*. 2002 Feb;26(2):249-56.
- 35) Thibodeau SN, French AJ, Roche PC, et al. Altered expression of hMSH2 and hMLH1 in tumors with microsatellite instability and genetic alterations in mismatch repair genes. *Cancer Res*. 1996 Nov 1;56(21):4836-40.
- 36) Torlakovic E, Skovland E, Snover DC, et al. Morphologic reappraisal of serrated colorectal polyps. *Am J Surg Pathol*. 2003 Jan;27(1):65-81.
- 37) Torlakovic E, Snover DC. Serrated adenomatous polyposis in humans. *Gastroenterology*. 1996 Mar;110(3):748-55.
- 38) VanRijnsoever M, Elsaleh H, Joseph D, McCaul K, Iacopetta B. CpG Island Methylator Phenotype is an Independent Precitor of Survival Benefit from 5-Fluorouracil in Stage III Colorectal Cancer. *Clin Cancer Res* 2003;9:2898-2903.
- 39) Vogelstein B, Fearon ER, Hamilton SR, et al. Genetic alterations during colorectal tumor development. *N Engl J Med* 1988;319:525-532.
- 40) Wang L, Cunningham JM, Winters JL, et al. BRAF mutations in colon cancer are not likely attributable to defective DNA mismatch repair. *Cancer Res*. 2003 Sep 1;63(17):5209-12.
- 41) Warner AS, Glick ME, Fogt F. Multiple large hyperplastic polyps of the colon coincident with adenocarcinoma. *Am J Gastroenterol*. 1994 Jan;89(1):123-5.
- 42) Williams GT. Metaplastic (hyperplastic) polyps of the large bowel: benign neoplasms after all? *Gut*. 1997 May;40(5):691-2.

- 43) Yao T, Kouzuki T, Kajiwara M, et al. 'Serrated' adenoma of the colorectum, with reference to its gastric differentiation and its malignant potential. *J Pathol.* 1999 Apr;187(5):511-7.
- 44) Yao T, Nishayama K, Oya M, et al, Multiple 'serrated adenocarcinomas' of the colon with a cell lineage common to metaplastic polyp and serrated adenoma. Case report of a new subtype of colonic adenocarcinoma with gastric differentiation. *J Pathol.* 2000 Mar;190(4):444-9.

Table 1. Major Morphologic Features of Sessile Serrated Polyps ^{10,36,37}

Abnormal Proliferation ^b / Dysmaturation ^c
Nuclear atypia in mid/upper crypts ^b
Oval nuclei in middle crypts ^c
Prominent nucleoli in middle/superficial crypts ^c
Dystrophic goblet cells ^b
Irregular distribution of goblet cells ^b
Mitoses in mid/upper crypts ^a
Architectural
Basal crypt dilatation ^{b,c}
Horizontal orientation of deep crypts ^{a,b}
Prominent serrations ^{a,c}
Inverted crypts ^c
Other Features
Lack of thickened basement membrane ^b
Focal loss of hMLH1 positivity ^{b,c}

a Torlakovic and Snover ³⁷

b Torlakovic and Skovland ³⁶

c Goldstein ¹⁰

**GASTRIC LUMPS AND BUMPS:
NO POLYP IS AN ISLAND**

Robert M Genta
Geneva University Hospitals
Geneva, Switzerland

INTRODUCTION

Most specimens received in the pathology laboratory as “gastric polyp” have distinctive features that allow their easy categorization into one of the major established classes of epithelial (hyperplastic, inflammatory, fundic, or adenomatous) or stromal proliferations. Common wisdom, embraced even by many modern textbooks of gastrointestinal pathology, holds that while adenomas have a high cancer risk and are frequently associated with synchronous adenocarcinomas, the malignant potential in hyperplastic polyps is very low and it is virtually absent in sporadic fundic polyps. As a consequence, the histopathological diagnosis of gastric adenoma may result in the inclusion of the patient into an endoscopic surveillance program, whereas no further workup and often only a limited follow-up is the usual clinical response to a diagnosis of hyperplastic, inflammatory, or fundic polyp.

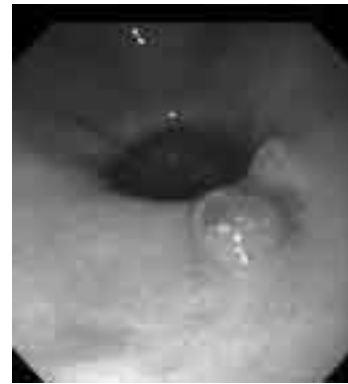Several studies published in the last few years suggest that this may be an oversimplification. Other types of gastric polyps display molecular alterations that may lead to neoplastic pathways, and may carry unappreciated risks. More questions must be asked and more extensive investigations may be warranted in some patients with other types of gastric polyps. The objective of this presentation is to discuss the possible significance of this recent body of information, particularly from the viewpoint of the practicing surgical pathologist.

CLASSIFICATION AND KEY FEATURES OF GASTRIC POLYPS

To ensure a uniform understanding of the terminology used here, this section briefly outlines the main characteristics and the generally accepted views of the three entities considered. Potentially relevant diagnostic and management issues raised by more recent findings are discussed in the subsequent sections. For the complete classification of gastric polyps followed here the reader is referred to Odze’s 2004 Textbook of Surgical Pathology of the GI Tract ¹.

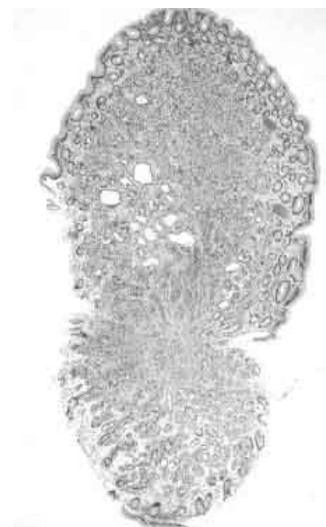
Hyperplastic polyps (Synonyms: Inflammatory, regenerative): they represent 70% to 80% of all gastric polyps, and arise most frequently on the background of an inflamed gastric mucosa. They are believed to originate as hyperproliferative responses to tissue injury; foveolar hyperplasia may be the elemental lesion. They are composed by elongated, grossly distorted, branching and dilated hyperplastic foveolae lying in an

edematous stroma rich in vasculature, and small, haphazardly distributed smooth muscle bundles; they contain varying degrees of chronic and active inflammation and granulation tissue. Hyperplastic polyps are usually small, measuring 0.5 - 1.5 cm in diameter, but may occasionally reach much larger dimensions. They are often multiple. Frequently, areas of the surface epithelium are eroded; this may result in chronic blood loss and iron-deficiency anemia, one of the most common clinical manifestations of hyperplastic polyps of the stomach. The prevalence of dysplasia has been reported to range from 1% to 20%, generally, but not in all series, more frequent in larger polyps². The overall malignant potential of hyperplastic polyps has been estimated to be less than 2%. Polypoid foveolar hyperplasia, gastric foveolar polyps and gastritis cystica polyposa (characteristic of post-Billroth I and II gastric stumps) may be considered variants of the same basic hyperproliferative foveolar lesion.



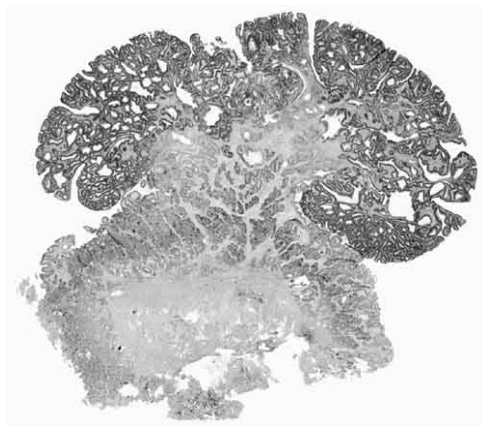
Gastroscopic view of an antral bleeding hyperplastic polyp

Fundic gland polyps: often classified as hamartomatous lesions, fundic gland polyps (generally referred to as “fundic polyps”) consist of smooth sessile circumscribed elevations (usually measuring < 0.5 cm) in the oxyntic mucosa. The basic lesion is one or more cystically dilated oxyntic gland. They may occur sporadically, in association with long-term use of proton-pump inhibitors (PPI), and in the familial adenomatous polyposis (FAP) syndrome. Although dissenting opinions have been published, sporadic and PPI-associated fundic polyps are traditionally believed to have neither malignant potential nor ominous associations; a “minimal” cancer risk is often mentioned for FAP-associated fundic polyps.



Low-power view of a fundic gland polyp, showing a few dilated oxyntic glands

Adenomas: gastric adenomas may occur sporadically and in association with FAP. Only the former are discussed here.



Pedunculated gastric adenoma

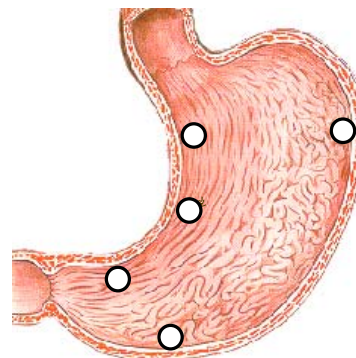
Adenomas are defined here as circumscribed, pedunculated or sessile proliferations of dysplastic epithelium without detectable invasion of the lamina propria. For the controversies that have arisen between Japanese and Western pathologists with regards to the distinction between adenoma and adenocarcinoma, the reader is referred to the

Padova³ and Vienna Classifications⁴ and to a historical accounts of the issue⁵. Sporadic gastric adenomas may be viewed as one of the possible steps in the development of adenocarcinoma: both arise most often on a background of chronic atrophic metaplastic gastritis; they share a common epidemiological pattern; the larger an adenomatous polyp the greater the probability that it contains foci of adenocarcinoma; and a synchronous adenocarcinoma in another area of the stomach has been found in up to 30% of patients with an adenoma. Most adenomas occur in the antrum and they are detected when they are solitary (~80%) and measure less than 2 cm.

CLINICO-PATHOLOGICAL CORRELATIONS

To paraphrase somewhat blasphemously John Donne, no polyp is an island. Gastric polyps (like gastric cancer) rarely if ever arise in a normal stomach. Although most gastroenterologists are aware of this, a thorough search for the background on which gastric polyps arise is uncommonly performed at the time the polyp is discovered. A few years ago, when *H. pylori* was suspected to be the cause of almost every possible gastric and extra-gastric ailment, a colleague and I designed a simple retrospective study aimed at determining the type of gastritis found at the time a gastric polyp was removed. Being in a large medical center with a digestive diseases division that was very active in clinical research and had been the foster home to the Updated Sydney System (the real home being in Pathology!), we assumed that virtually every polyp would be accompanied by a set of representative biopsy specimens from the rest of the stomach. Although the exact figures are now forgotten, no more than one third of the one hundred-something polyps removed in the previous five years had any synchronous biopsy specimens, and in less than 10% of the cases was a topographically defined set of specimens available.

Clearly, the study could not be carried out. I suspect that the situation is not very different in most other centers, and it is perhaps our responsibility as pathologists to deliver the message to our clinical colleagues: for an accurate and perhaps even predictive diagnosis of gastric polyps, let us have a good look at the rest of the gastric mucosa.



The five biopsy mapping sites recommended by the Updated Sydney System

Hyperplastic polyps

H. PYLORI, AND CHEMICAL INJURY

Foveolar hyperplasia is a compensatory response to increased cellular exfoliation from the surface epithelium that can be viewed as a visual surrogate for increased epithelial cell turnover^{6,7}. While greatly hyperplastic foveolae are easily recognized, lesser degrees of foveolar elongation and increased tortuosity may not be apparent. As an empirical tool, it has been suggested that if more than four cross sections of the same pit are seen in a well-oriented gastric biopsy specimen, one can confidently diagnose foveolar hyperplasia⁸. The diagnosis of hyperplasia is also facilitated by the finding of

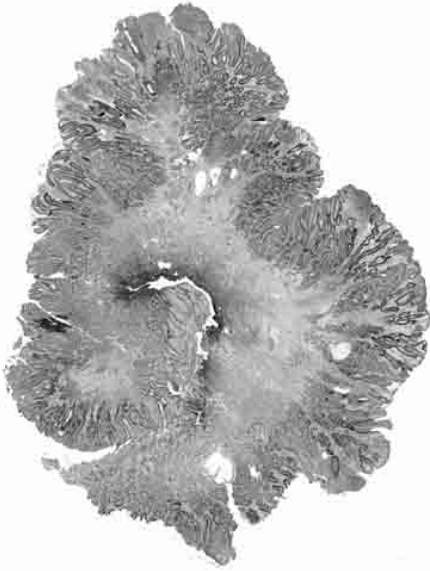
hyperchromatic nuclei and mitotic activity reaching an increased height of the pit, and by signs of cellular immaturity (mucin depletion, a cuboidal shape, and a high nucleocytoplasmic ratio). Foveolar hyperplasia has long been recognized as a prominent feature of bile reflux gastritis⁶. More recently, hyperplasia it has been emphasized as a key feature of the gastropathy associated with long-term NSAIDs treatment⁸. Lesser degrees of hyperplasia are commonly seen in *H. pylori* gastritis, but when hyperplasia is marked and diffuse it suggests co-existent chemical injury⁹.

These two broad categories of conditions (chronic active gastritis caused by *H. pylori* and chemical injury) are the ones most commonly associated with hyperplastic polyps. In *H. pylori* gastritis (or in patients who may have had a long-standing *H. pylori* gastritis that progressed to atrophy with neither activity nor detectable bacteria) extreme focal foveolar hyperplasia, perhaps in response to a localized more severe injury (erosion, superficial ulcer) may evolve into an agglomerate of highly hypertrophic foveolae, and the long-standing processes of inflammation, repair, and proliferation result into the features of a hyperplastic polyp: grossly distorted, long, dilated pits, inflammation, granulation tissue and erosions. Removal of the injury (*i.e.*, eradication of *H. pylori*) has been shown to cause the regression of hyperplastic polyps in a high proportion of patients (up to 70% in one study)¹⁰.

A histologically similar picture, but usually associated with larger and more expansive lesions, can be found in areas adjacent to gastrojejunostomy stomas. The initial step is likely foveolar hyperplasia in response to pancreaticoduodenal secretions as well as acids, bile salts, and lysolecithin, the last being produced by the action of phospholipase in pancreatic juice on the lecithin in bile. Duodenogastric reflux results in disruption of the mucus barrier and the direct action of chemicals on the surface epithelium. Loss of the mucous barrier allows back-diffusion of hydrogen ions and secondary injurious effects¹¹. The combined injury leads to accelerated exfoliation of surface epithelial cells and a histamine-mediated vascular response that manifests as edema and hyperemia. Repetitive injury may lead to the release of other pro-inflammatory agents, such as platelet-derived growth factor, which among its many actions stimulates smooth muscle and, later on, fibroblastic proliferation⁷. The first macroscopically visible lesion is polypoid foveolar hyperplasia, which may evolve into the large masses of hyperplastic polyps found in some patients at the gastrectomy site.

FROM HYPERPLASIA TO CARCINOMA

Both isolated hyperplastic polyps and the polypoid aggregates found at gastrectomy sites have a low but definite potential for the development of malignancy. Between 1% and 20% of hyperplastic polyps have been found to harbor foci of dysplasia; furthermore, mutations of the *p53* gene, chromosomal aberrations, and microsatellite instability have been detected in these polyps¹²⁻¹⁶. In the presence of such a wide array of evidence supporting the biological plausibility of a neoplastic evolution, what should the pathologist's attitude be?



Hyperplastic polyp

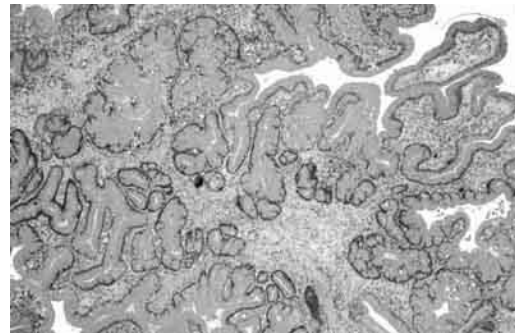
A PRACTICAL APPROACH TO HYPERPLASTIC POLYPS

Two considerations may help put these potentially worrisome findings into perspective. First, the polyp under examination is no longer in the patient; if dysplasia, or even non-invasive carcinoma, is present, it has been removed and cured. Second, the molecular studies carried out so far were designed to acquire insights into possible neoplastic mechanisms, not to develop predictive tests: thus, in the clinical setting the performance of immunostains to detect p53 accumulation or microsatellite instability (both easily available and accurate) or gene arrays, would yield results that can neither be interpreted nor used.

More important, in my view, is to be able to evaluate the stomach in which the polyp has arisen. When a hyperplastic polyp of any size with or without dysplasia (by far the more

common occurrence) is diagnosed, the gastroenterologist should be personally informed and, unless one has been done recently, a full set of topographically defined biopsy specimens (“gastric mapping”) needs to be obtained. If *H. pylori*-gastritis is present, eradication is warranted, with a follow-up endoscopy after a few months to monitor not only the successful eradication of *H. pylori*, but also the possible recurrence of polyps. If extensive atrophy and metaplasia are found, the patient should be considered at risk for gastric cancer, the polyp could be viewed as an alarming lesion, and an individualized surveillance plan (for which guidelines do not exist as yet) should be implemented¹⁷. If the polyp is obtained from a gastrectomy site, in the absence of dysplasia, the optimal management remains uncertain.

Although the European literature has emphasized a high risk for gastric stump cancer, particularly after Billroth I operations¹⁸, a landmark study conducted in the Netherlands revealed a 0.2% overall incidence of adenocarcinoma in post-gastrectomy patients followed for 15 to 46 years. In North America, although case reports and calls for surveillance are occasionally published, a low incidence of cancer has generally been found^{19,20}.



Dilated convoluted glands characteristic of hyperplastic polyps

Fundic polyps: a distant connection

The dilated oxyntic glands that form the small mucosal bumps in the mucosa of the gastric corpus are unlikely candidates for the development of malignancy. The epithelium is that of a mixture of flattened oxyntic, chief, and mucous cells. Dysplastic changes are virtually never seen, although some authors have insistently disputed the entirely benign nature of these polyps²¹.

An association of FAP-associated fundic polyps with colonic neoplasia is not unexpected, since in that nosological context the two are expressions of the same inherited condition.

In the last few years, there have been several reports of patients with sporadic fundic polyps and a colorectal neoplasia (adenomas or carcinomas), and a number of investigators have conducted both retrospective and prospective studies to better define the strength of the association. The conclusions of the most recent of these studies¹⁵ are astonishing: 29 of 64 patients (45.3%) with sporadic fundic polyps had colorectal neoplasia (including 8 adenocarcinomas, 3 adenomas with intraepithelial neoplasia, and 18 tubular adenomas). In the control group, similar in size and demographic characteristics, only 6 patients (9.3%) had adenomas. Although there may be considerable methodological problems with the study (judging from the information available in the article), the authors' conclusions ("Our results suggest that it is necessary to conduct a careful diagnostic work-up of the colon in patients with gastric fundic gland polyps") should be taken seriously. It is certainly worthwhile to carry out larger rigorously designed studies in different populations to explore this puzzling association.

Another interesting and potentially important finding is the recent discovery that a significant proportion of sporadic fundic polyps (even those arising in apparent response to long-term PPI use) of have genetic alterations involving beta-catenin stabilization, as do those associated with FAP^{22,23}. Abnormal expression of the E-cadherin/catenin membrane complex is common in esophageal adenocarcinoma (as well as in other tumors) and occurs early in the dysplasia/carcinoma sequence in Barrett's esophagus, indicating that disturbances in this cell adhesion complex might be important in tumorigenesis and tumor progression in this disorder²⁴. The significance of these findings in fundic polyps may not yet be apparent, but the view that these polyps are completely devoid of malignant potential may deserve a second look.

The pathologist's role in after the diagnosis of a fundic polyp is limited. No specific studies are warranted on the polyps themselves. However, particularly in the case of multiple polyps, alerting clinicians about the possibility of FAP and reminding them about the possible connection with colorectal neoplasia may be appropriate. If other biopsy specimens from the corpus are available, the telltale signs of chronic PPI use (dilated oxyntic glands, protruding hyperplastic oxyntic cells, and *H. pylori* located in the lower portions of the glands as well as within the oxyntic cell canaliculi) should also be reported, suggesting that the fundic polyps may be related to pharmacological acid suppression.

Adenomas and the goblet of mucus

The approach to gastric adenomas has not been changed significantly by molecular studies that have confirmed its neoplastic nature. One of the most interesting recent studies reports that the distinction of the type (“intestinal” versus “gastric”) may further define the cancer risk (greater in the former)²⁵. In the presence of adenomas, however, irrespective of their cellular make up, a complete gastric bioptic mapping is necessary to determine the phenotype of gastritis on which the adenoma arises. As stated above, metaplastic atrophic gastritis with an adenoma is an indication for an aggressive surveillance program.

SUMMARY

No published guidelines exist for the managements of most types of gastric polyps. Since cancer risk in these heterogeneous patients has not been quantified, the pathologist can influence clinicians’ attitudes and ultimately benefit their patients by suggesting extensive biopsy protocols that elucidate the status of the gastric mucosa and help make informed decisions on the design of individualized follow-up protocols.

REFERENCES

1. Turner JR, Odze RD. Polyps of the stomach. Odze RD, Goldblum JR, Crawford JM (eds). *Surgical Pathology of the GI Tract, Liver, Biliary Tract, and Pancreas* Philadelphia: Saunders, 2004:267-294.
2. Ginsberg GG, al Kawas FH, Fleischer DE et al. Gastric polyps: relationship of size and histology to cancer risk. *Am J Gastroenterol* 1996;91:714-717.
3. Rugge M, Correa P, Dixon MF et al. Gastric dysplasia: the Padova international classification. *Am J Surg Pathol* 2000;24:167-176.
4. Schlemper RJ, Riddell RH, Kato Y et al. The Vienna classification of gastrointestinal epithelial neoplasia. *Gut* 2000;47:251-255.
5. Genta, R. M. Gastric Dysplasia in the East and West. *Current Gastroenterology Reports* 2. 2001.
6. Dixon MF, O'Connor HJ, Axon AT et al. Reflux gastritis: distinct histopathological entity? *J Clin Pathol* 1986;39:524-530.
7. Dixon MF. The Components of Gastritis: Histology and Pathogenesis. Graham DY, Genta RM, Dixon MF (eds). *Gastritis* Philadelphia: Lippincott Williams & Wilkins, 1999:51-66.
8. Quinn CM, Bjarnason I, Price AB. Gastritis in patients on non-steroidal anti-inflammatory drugs. *Histopathology* 1993;23:341-348.
9. El Zimaity HM, Genta RM, Graham DY. Histological features do not define NSAID-induced gastritis. *Hum Pathol* 1996;27:1348-1354.
10. Ohkusa T, Takashimizu I, Fujiki K et al. Disappearance of hyperplastic polyps in the stomach after eradication of *Helicobacter pylori*. A randomized, clinical trial. *Ann Intern Med* 1998;129:712-715.
11. Hawkey CJ. Nonsteroidal anti-inflammatory drug gastropathy. *Gastroenterology* 2000;119:521-535.

12. Nogueira AM, Carneiro F, Seruca R et al. Microsatellite instability in hyperplastic and adenomatous polyps of the stomach. *Cancer* 1999;86:1649-1656.
13. Murakami K, Mitomi H, Yamashita K et al. p53, but not c-Ki-ras, mutation and down-regulation of p21WAF1/CIP1 and cyclin D1 are associated with malignant transformation in gastric hyperplastic polyps. *Am J Clin Pathol* 2001;115:224-234.
14. Abraham SC, Park SJ, Mugartegui L et al. Sporadic fundic gland polyps with epithelial dysplasia : evidence for preferential targeting for mutations in the adenomatous polyposis coli gene. *Am J Pathol* 2002;161:1735-1742.
15. Jung A, Vieth M, Maier O et al. Fundic gland polyps (Elster's cysts) of the gastric mucosa. A marker for colorectal epithelial neoplasia? *Pathol Res Pract* 2002;198:731-734.
16. Weiss MM, Kuipers EJ, Postma C et al. Genome wide array comparative genomic hybridisation analysis of premalignant lesions of the stomach. *J Clin Pathol : Mol Pathol* 2003;56:293-298.
17. Abraham SC, Singh VK, Yardley JH et al. Hyperplastic polyps of the stomach: associations with histologic patterns of gastritis and gastric atrophy. *Am J Surg Pathol* 2001;25:500-507.
18. Pointner R, Schwab G, Konigsrainer A et al. Gastric stump cancer: etiopathological and clinical aspects. *Endoscopy* 1989;21:115-119.
19. Safatle-Ribeiro AV, Ribeiro U, Jr., Reynolds JC. Gastric stump cancer: what is the risk? *Dig Dis* 1998;16:159-168.
20. Schuman BM, Waldbaum JR, Hiltz SW. Carcinoma of the gastric remnant in a U.S. population. *Gastrointest Endosc* 1984;30:71-73.
21. Declich P, Ambrosiani L, Grassini R et al. Fundic gland polyps: a still elusive entity on the eve of the year 2000. *Pol J Pathol* 2000;51:3-8.
22. Torbenson M, Lee JH, Cruz-Correa M et al. Sporadic fundic gland polyposis: a clinical, histological, and molecular analysis. *Mod Pathol* 2002;15:718-723.
23. Sekine S, Shibata T, Yamauchi Y et al. Beta-catenin mutations in sporadic fundic gland polyps. *Virchows Arch* 2002;440:381-386.
24. Washington K, Chiappori A, Hamilton K et al. Expression of beta-catenin, alpha-catenin, and E-cadherin in Barrett's esophagus and esophageal adenocarcinomas. *Mod Pathol* 1998;11:805-813.
25. Abraham SC, Montgomery EA, Singh VK et al. Gastric adenomas: intestinal-type and gastric-type adenomas differ in the risk of adenocarcinoma and presence of background mucosal pathology. *Am J Surg Pathol* 2002;26:1276-1285.